blood® Special Report

Check for updates

# The International Consensus Classification of Mature Lymphoid Neoplasms: a report from the Clinical Advisory Committee

Elias Campo,[1] Elaine S. Jaffe,[2] James R. Cook,[3] Leticia Quintanilla-Martinez,[4] Steven H. Swerdlow,[5] Kenneth C. Anderson,[6] Pierre Brousset,[7] Lorenzo Cerroni,[8] Laurence de Leval,[9] Stefan Dirnhofer,[10] Ahmet Dogan,[11] Andrew L. Feldman,[12] Falko Fend,[4] Jonathan W. Friedberg,[13] Philippe Gaulard,[14,15] Paolo Ghia,[16] Steven M. Horwitz,[17] Rebecca L. King,[12] Gilles Salles,[17] Jesus San-Miguel,[18] John F. Seymour,[19] Steven P. Treon,[6] Julie M. Vose,[20] Emanuele Zucca,[21] Ranjana Advani,[22] Stephen Ansell,[23] Wing-Yan Au,[24] Carlos Barrionuevo,[25] Leif Bergsagel,[26] Wing C. Chan,[27] Jeffrey I. Cohen,[28] Francesco d'Amore,[29] Andrew Davies,[30] Brunangelo Falini,[31] Irene M. Ghobrial,[6,32] John R. Goodlad,[33] John G. Gribben,[34] Eric D. Hsi,[35] Brad S. Kahl,[36] Won-Seog Kim,[37] Shaji Kumar,[23] Ann S. LaCasce,[6] Camille Laurent,[7] Georg Lenz,[38] John P. Leonard,[39] Michael P. Link,[40] Armando Lopez-Guillermo,[41] Maria Victoria Mateos,[42] Elizabeth Macintyre,[43] Ari M. Melnick,[44] Franck Morschhauser,[45] Shigeo Nakamura,[46] Marina Narbaitz,[47] Astrid Pavlovsky,[48] Stefano A. Pileri,[49] Miguel Piris,[50] Barbara Pro,[51] Vincent Rajkumar,[12] Steven T. Rosen,[52] Birgitta Sander,[53] Laurie Sehn,[54] Margaret A. Shipp,[6] Sonali M. Smith,[55] Louis M. Staudt,[56] Catherine Thieblemont,[57,58] Thomas Tousseyn,[59] Wyndham H. Wilson,[56] Tadashi Yoshino,[60] Pier-Luigi Zinzani,[61] Martin Dreyling,[62] David W. Scott,[54] Jane N. Winter,[63] and Andrew D. Zelenetz[17,64]

[1]Haematopathology Section, Hospital Clínic of Barcelona, Institut d'Investigaciones Biomèdiques August Pi I Sunyer (IDIBAPS), University of Barcelona, Centro de Investigación Biomédica en Red de Cancer (CIBERONC), Barcelona, Spain; [2]Hematopathology Section, Laboratory of Pathology, Center for Cancer Research, National Cancer Institute, Bethesda, MD; [3]Pathology and Laboratory Medicine Institute, Cleveland Clinic, Cleveland, OH; [4]Institute of Pathology and Neuropathology, Eberhard Karls University of Tübingen and Comprehensive Cancer Center, University Hospital Tübingen, Tübingen, Germany; [5]Department of Pathology, University of Pittsburgh School of Medicine, University of Pittsburgh, Pittsburgh, PA; [6]Dana-Farber Cancer Institute, Boston, MA; [7]Department of Pathology, Institut Universitaire du Cancer de Toulouse-Oncopole, and Laboratoire d'Excellence Toulouse Cancer, Toulouse, France; [8]Department of Dermatology, Medical University of Graz, Graz, Austria; [9]Institute of Pathology, Department of Laboratory Medicine and Pathology, Lausanne University Hospital and Lausanne University, Lausanne, Switzerland; [10]Institute of Medical Genetics and Pathology, University Hospital Basel, University of Basel, Basel, Switzerland; [11]Laboratory of Pathology, Memorial Sloan Kettering Cancer Center, New York, NY; [12]Department of Laboratory Medicine and Pathology, Mayo Clinic, Rochester, MN; [13]Wilmot Cancer Institute, University of Rochester, Rochester, NY; [14]Department of Pathology, University Hospital Henri Mondor, Assistance Publique-Hôpitaux de Paris (AP-HP), Créteil, France; [15]Mondor Institute for Biomedical Research, INSERM U955, Faculty of Medicine, University of Paris-Est Créteil, Créteil, France; [16]Strategic Research Program on Chronic Lymphocytic Leukemia, Division of Experimental Oncology, IRCCS Ospedale San Raffaele and Università Vita-Salute San Raffaele, Milan, Italy; [17]Lymphoma Service, Department of Medicine, Memorial Sloan Kettering Cancer Center, New York, NY; [18]Clínica Universidad de Navarra, Centro de Investigación Médica Aplicada, Instituto de Investigación Sanitaria de Navarra, CIBERONC, Pamplona, Spain; [19]Peter MacCallum Cancer Centre and Royal Melbourne Hospital, Melbourne, VIC, Australia; [20]Division of Hematology-Oncology, Department of Internal Medicine, University of Nebraska Medical Center, University of Nebraska, Omaha, NE; [21]Oncology Institute of Southern Switzerland, Ente Ospedaliero Cantonale, and Institute of Oncology Research, Università della Svizzera Italiana, Bellinzona, Switzerland; [22]Stanford Cancer Center, Blood and Marrow Transplant Program, Stanford University, Stanford, CA; [23]Division of Hematology, Department of Medicine, Mayo Clinic, Rochester, MN; [24]Blood-Med Clinic, Hong Kong, People's Republic of China; [25]Department of Pathology, Instituto Nacional de Enfermedades Neoplásicas, Faculty of Medicine, Universidad Nacional Mayor de San Marcos, Lima, Peru; [26]Division of Hematology, Department of Internal Medicine, Mayo Clinic, Phoenix, AZ; [27]Department of Pathology, City of Hope National Medical Center, Duarte, CA; [28]Medical Virology Section, Laboratory of Infectious Diseases, National Institutes of Health, National Institute of Allergy and Infectious Diseases, Bethesda, MD; [29]Department of Hematology, Aarhus University Hospital, Aarhus, Denmark; [30]Cancer Research UK Centre, Centre for Cancer Immunology, Faculty of Medicine, Southampton General Hospital, University of Southampton, Southampton, United Kingdom; [31]Institute of Hematology and Center for Hemato-Oncology Research, Hospital of Perugia, University of Perugia , Perugia, Italy; [32]Harvard Medical School, Harvard University, Boston, MA; [33]National Health Service Greater Glasgow and Clyde, Glasgow, United Kingdom; [34]Department of Haemato-Oncology, Barts Cancer Institute, Queen Mary University of London, London, United Kingdom; [35]Department of Pathology, Wake Forest School of Medicine, Wake Forest University, Winston-Salem, NC; [36]Oncology Division, Washington University School of Medicine, Washington University in St. Louis, St. Louis, MO; [37]Hematology and Oncology, Samsung Medical Center, Sungkyunkwan University School of Medicine, Seoul, South Korea; [38]Department of Medicine A, Hematology, Oncology and Pneumology, University Hospital Muenster, Muenster, Germany; [39]Weill Department of Medicine, Weill Medical College, Cornell University, New York, NY; [40]Department of Pediatrics, Division of Pediatric Hematology-Oncology, Stanford University School of Medicine, Stanford University, Stanford, CA; [41]Department of Hematology, Hospital Clínic, IDIBAPS, University of Barcelona, Barcelona, Spain; [42]Department of Hematology, Hospital Universitario de Salamanca, Instituto de Investigación Biomédica de Salamanca, Centro de Investigación del Cancer, Universidad de Salamanca, Salamanca, Spain; [43]Laboratoire d'Onco-Hématologie, AP-HP, Hôpital Necker-Enfants Malades, Université de Paris Cité and Institut Necker-Enfants Malades, Paris, France; [44]Division of Hematology and Oncology, Weill Medical College, Cornell University, New York, NY; [45]Department of Hematology, Centre Hospitalier Universitaire de Lille, University Lille, Lille, France; [46]Department of Pathology and Laboratory Medicine, Nagoya University Hospital, Nagoya, Japan; [47]Department of Pathology, Instituto de Investigaciones Hematológicas, Academia Nacional de Medicina and Fundacion para combatir la leucemia (FUNDALEU), Buenos Aires, Argentina; [48]Fundación para Combatir la Leucemia (FUNDALEU), Centro de Hematología Pavlovsky, Buenos Aires, Argentina; [49]Haematopathology Division, IRCCS, Istituto Europeo di Oncologia, Milan, Italy; [50]Jiménez Díaz Foundation University Hospital, Universidad Autónoma de Madrid, Madrid, Spain; [51]Division of Hematology and Oncology, Department of Medicine, Feinberg School of Medicine, Northwestern University, Chicago, IL; [52]Beckman Research Institute, and Department of Hematology & Hematopoietic Cell Transplantation, City of Hope National Medical Center, Duarte, CA; [53]Department of Laboratory Medicine, Karolinska Institutet, Stockholm, Sweden; [54]Centre for Lymphoid Cancer, British Columbia Cancer Agency, Vancouver, BC, Canada; [55]Section of Hematology/Oncology, University of Chicago, Chicago, IL; [56]Lymphoid Malignancies Branch, Center for Cancer Research, National Cancer Institute, National Institutes of Health, Bethesda, MD; [57]Service Hémato-Oncologie, AP-HP, Hôpital Saint-Louis, Paris,

Downloaded from ashpublications.org/blood/article-pdf/140/11/1229/1921035/bloodbld2022015851c.pdf by guest on 15 September 2026

France; [58]DMU-DHI, Université de Paris-Paris Diderot, Paris, France; [59]Department of Pathology, Universitair Ziekenhuis Leuven Hospitals, Leuven, Belgium; [60]Department of Pathology, Graduate School of Medicine, Dentistry, and Pharmaceutical Sciences, Okayama University, Okayama, Japan; [61]Azienda Ospedaliero-Universitaria di Bologna, Istituto di Ematologia "Seragnoli", Dipartimento di Medicina Specialistica, Diagnostica e Sperimentale, Università di Bologna, Bologna, Italy; [62]Department of Medicine III, Ludwig-Maximilians-University Hospital, Munich, Germany; [63]Feinberg School of Medicine, Northwestern University, Chicago, IL; and [64]Weill Medical College, Cornell University, New York, NY

**Since the publication of the Revised European-American Classification of Lymphoid Neoplasms in 1994, subsequent updates of the classification of lymphoid neoplasms have been generated through iterative international efforts to achieve broad consensus among hematopathologists, geneticists, molecular scientists, and clinicians. Significant progress has recently been made in the characterization of malignancies of the immune system, with many new insights provided by genomic studies. They have led to this proposal. We have followed the same process that was successfully used for the third and fourth editions of the World Health Organization Classification of Hematologic Neoplasms. The definition, recommended studies, and criteria for the diagnosis of many entities have been extensively refined. Some categories considered provisional have now been upgraded to definite entities. Terminology for some diseases has been revised to adapt nomenclature to the current knowledge of their biology, but these modifications have been restricted to well-justified situations. Major findings from recent genomic studies have impacted the conceptual framework and diagnostic criteria for many disease entities. These changes will have an impact on optimal clinical management. The conclusions of this work are summarized in this report as the proposed International Consensus Classification of mature lymphoid, histiocytic, and dendritic cell tumors.**

# Introduction

The publication of the Revised European-American Classification of Lymphoid Neoplasms (REAL) in 1994[1] and its subsequent validation across the world in 1997[2] represented a change of paradigm in the classification of these tumors. This classification provided a novel framework for the recognition of individual disease entities based on a constellation of features, including morphology, immune phenotype, clinical presentation, and genomics. This effort led to the World Health Organization (WHO) classification[3] published in 2001, which extended the same conceptual approach to all hematopoietic and lymphoid neoplasms. The process was a joint effort of the Society for Hematopathology (SH) and the European Association for Haematopathology (EAHP) together with hematologists, oncologists, and scientists through joint Clinical Advisory Committees (CACs) at which collegial discussions led to broad consensus.[4,5] The classification rapidly became the international standard, with publication of subsequent updates in 2008 and 2017.[4-7] Since 2017, we have seen significant progress in the characterization of malignancies of the immune system, with many new insights provided by genomic studies. Initial planning and discussion for the current International Consensus Classification (ICC) took place in April 2021 at the twentieth meeting of the EAHP/SH. An international committee undertook the organization of the next CAC, which was held in September 2021. The subsequent discussions included 14 working groups (supplemental Table 1, available on the *Blood* Web site) with broad international participation. The conclusions of that meeting are summarized in this report with the proposal of the ICC (Table 1).

The definition of most entities remains unchanged, but criteria for diagnosis and recommended ancillary studies have been extensively refined. Some categories considered provisional in 2017 have now been upgraded to definite entities. Terminology for some diseases has been revised to adapt nomenclature to the current knowledge of their biology, but these modifications have been restricted to well-justified situations. Some categories such as multiple myeloma (MM) and Epstein-Barr virus (EBV)–positive T-cell lymphoproliferative disorders (LPDs) in children have undergone major revision. Major findings from recent genomic studies have had an impact on the conceptual framework of some diseases. This article will review the major revisions in the criteria and definition of mature lymphoid, histiocytic, and dendritic cell tumors (Tables 2–4).

# Mature B-cell neoplasms

## Chronic lymphocytic leukemia

The diagnostic criteria for chronic lymphocytic leukemia (CLL) and monoclonal B-cell lymphocytosis (MBL) are well established.[5,8] Immunophenotype is determined by flow cytometry with a panel of CD19, CD5, CD23, and CD20 kappa and lambda that may be expanded in selected patients with CD43, CD79b, CD81, CD200, CD10, and ROR1 to clarify the diagnosis.[8] The mutational status of the IGHV and *TP53*/17p alterations need to be evaluated at the time when patients require treatment.[8] Although the (epi)genomic profile of CLL has been intensively investigated in the last decade,[9-11] the clinical translation of the vast majority of the findings still requires further study. Factors likely to have significant clinical relevance include subclonal *TP53* mutations with low variant allelic frequency (<10%), BCR stereotypes (eg, stereotypes 2 and 8), specific mutated genes (eg, *NOTCH1*, *SF3B1*, and *BIRC3*), and the IGLV3-21$^{R110}$ mutation.[12-17] Complex karyotype, defined as ≥3 aberrations, is currently applied in alignment with thresholds derived from other disease settings.[8] However, in CLL, a distinct threshold of ≥5 abnormalities may better stratify very-high-risk patients.[18] Although the prognostic impact of all these and other parameters has been shown in retrospective studies, clinical implementation will require methodologic evaluation, standardization, and validation in prospective studies.

Downloaded from ashpublications.org/blood/article-pdf/140/11/1229/1921035/bloodbld2022015851c.pdf by guest on 15 September 2026

## Table 1. International Consensus Classification of mature lymphoid and histiocytic/dendritic cell neoplasms

**Mature B-cell neoplasms**

- Chronic lymphocytic leukemia/small lymphocytic lymphoma
- Monoclonal B-cell lymphocytosis
  - Chronic lymphocytic leukemia type
  - Non-chronic lymphocytic leukemia type
- B-cell prolymphocytic leukemia
- Splenic marginal zone lymphoma
- Hairy cell leukemia
- *Splenic B-cell lymphoma/leukemia, unclassifiable*
  - *Splenic diffuse red pulp small B-cell lymphoma*
  - *Hairy cell leukemia-variant*
- Lymphoplasmacytic lymphoma
  - Waldenström macroglobulinemia
- Immunoglobulin M (IgM) monoclonal gammopathy of undetermined significance (MGUS)
  - IgM MGUS, plasma cell type*
  - IgM MGUS, not otherwise specified (NOS)*
- Primary cold agglutinin disease*
- Heavy chain diseases
  - Mu heavy chain disease
  - Gamma heavy chain disease
  - Alpha heavy chain disease
- Plasma cell neoplasms
  - Non-IgM MGUS
  - Multiple myeloma (plasma cell myeloma)*
    - Multiple myeloma, NOS
    - Multiple myeloma with recurrent genetic abnormality
      - Multiple myeloma with *CCND* family translocation
      - Multiple myeloma with *MAF* family translocation
      - Multiple myeloma with *NSD2* translocation
      - Multiple myeloma with hyperdiploidy
  - Solitary plasmacytoma of bone
  - Extraosseous plasmacytoma
- Monoclonal Ig deposition diseases
  - Ig light chain amyloidosis (AL)*
  - Localized AL amyloidosis*
  - Light chain and heavy chain deposition disease
- Extranodal marginal zone lymphoma of mucosa-associated lymphoid tissue (MALT lymphoma)
- Primary cutaneous marginal zone lymphoproliferative disorder*
- Nodal marginal zone lymphoma
  - *Pediatric nodal marginal zone lymphoma*
- Follicular lymphoma
  - In situ follicular neoplasia
  - Duodenal-type follicular lymphoma
- *BCL2-R–negative, CD23-positive follicle center lymphoma*
- Primary cutaneous follicle center lymphoma
- Pediatric-type follicular lymphoma

## Table 1. (continued)

- Testicular follicular lymphoma*
- Large B-cell lymphoma with *IRF4* rearrangement*
- Mantle cell lymphoma
  - In situ mantle cell neoplasia
  - Leukemic non-nodal mantle cell lymphoma
- Diffuse large B-cell lymphoma, NOS
  - Germinal center B-cell subtype
  - Activated B-cell subtype
- *Large B-cell lymphoma with 11q aberration**
- Nodular lymphocyte predominant B-cell lymphoma*
- T cell/histiocyte-rich large B-cell lymphoma
- Primary diffuse large B-cell lymphoma of the central nervous system
- Primary diffuse large B-cell lymphoma of the testis*
- Primary cutaneous diffuse large B-cell lymphoma, leg type
- Intravascular large B-cell lymphoma
- *HHV-8 and Epstein-Barr virus–negative primary effusion-based lymphoma**
- Epstein-Barr virus–positive mucocutaneous ulcer*
- Epstein-Barr virus–positive diffuse large B-cell lymphoma, NOS
- Diffuse large B-cell lymphoma associated with chronic inflammation
  - Fibrin-associated diffuse large B-cell lymphoma
- Lymphomatoid granulomatosis
- Epstein-Barr virus–positive polymorphic B-cell lymphoproliferative disorder, NOS*
- ALK-positive large B-cell lymphoma
- Plasmablastic lymphoma
- HHV-8–associated lymphoproliferative disorders
  - Multicentric Castleman disease
  - HHV-8–positive germinotropic lymphoproliferative disorder
  - HHV-8–positive diffuse large B-cell lymphoma, NOS
  - Primary effusion lymphoma
- Burkitt lymphoma
- High-grade B-cell lymphoma, with *MYC* and *BCL2* rearrangements*
- *High-grade B-cell lymphoma with MYC and BCL6 rearrangements**
- High-grade B-cell lymphoma, NOS
- Primary mediastinal large B-cell lymphoma
- Mediastinal gray-zone lymphoma*

**Classic Hodgkin lymphoma**

- Nodular sclerosis classic Hodgkin lymphoma
- Lymphocyte-rich classic Hodgkin lymphoma
- Mixed cellularity classic Hodgkin lymphoma
- Lymphocyte-depleted classic Hodgkin lymphoma

**Mature T-cell and NK-cell neoplasms**

- T-cell prolymphocytic leukemia
- T-cell large granular lymphocytic leukemia

*Italic font* indicates provisional tumor entities.

*Changes from the 2016 WHO classification.

†These lesions are classified according to the lymphoma to which they correspond.

Downloaded from ashpublications.org/blood/article-pdf/140/11/1229/1921035/bloodbld2022015851c.pdf by guest on 15 September 2026

**Table 1. (continued)**

| |
|---|
| *Chronic lymphoproliferative disorder of NK cells* |
| Adult T-cell leukemia/lymphoma |
| Epstein-Barr virus–positive T-cell/NK-cell lymphoproliferative disorders of childhood* |
| Hydroa vacciniforme lymphoproliferative disorder |
| Classic |
| Systemic |
| Severe mosquito bite allergy |
| Chronic active Epstein-Barr virus disease, systemic (T-cell and NK-cell phenotype) |
| Systemic Epstein-Barr virus–positive T-cell lymphoma of childhood |
| Extranodal NK/T-cell lymphoma, nasal type |
| Aggressive NK-cell leukemia |
| *Primary nodal Epstein-Barr virus–positive T-cell/NK-cell lymphoma** |
| Enteropathy-associated T-cell lymphoma |
| Type II refractory celiac disease* |
| Monomorphic epitheliotropic intestinal T-cell lymphoma |
| Intestinal T-cell lymphoma, NOS |
| Indolent clonal T-cell lymphoproliferative disorder of the gastrointestinal tract* |
| Indolent NK-cell lymphoproliferative disorder of the gastrointestinal tract* |
| Hepatosplenic T-cell lymphoma |
| Mycosis fungoides |
| Sézary syndrome |
| Primary cutaneous CD30$^+$ T-cell lymphoproliferative disorders |
| Lymphomatoid papulosis |
| Primary cutaneous anaplastic large cell lymphoma |
| Primary cutaneous small/medium CD4$^+$ T-cell lymphoproliferative disorder |
| Subcutaneous panniculitis-like T-cell lymphoma |
| Primary cutaneous gamma-delta T-cell lymphoma |
| Primary cutaneous acral CD8$^+$ T-cell lymphoproliferative disorder* |
| Primary cutaneous CD8$^+$ aggressive epidermotropic cytotoxic T-cell lymphoma |
| Peripheral T-cell lymphoma, NOS |
| Follicular helper T-cell lymphoma* |
| Follicular helper T-cell lymphoma, angioimmunoblastic type (angioimmunoblastic T-cell lymphoma) |
| Follicular helper T-cell lymphoma, follicular type |
| Follicular helper T-cell lymphoma, NOS |
| Anaplastic large cell lymphoma, ALK positive |
| Anaplastic large cell lymphoma, ALK negative |
| Breast implant–associated anaplastic large cell lymphoma |
| **Immunodeficiency-associated lymphoproliferative disorders** |
| Posttransplant lymphoproliferative disorders |
| Nondestructive posttransplant lymphoproliferative disorders |
| Plasmacytic hyperplasia posttransplant lymphoproliferative disorder |
| Infectious mononucleosis posttransplant lymphoproliferative disorder |
| Florid follicular hyperplasia posttransplant lymphoproliferative disorder |
| Polymorphic posttransplant lymphoproliferative disorder |
| Monomorphic posttransplant lymphoproliferative disorder (B-cell and T-cell/NK-cell types)† |
| Classic Hodgkin lymphoma posttransplant lymphoproliferative disorder† |
| Other iatrogenic immunodeficiency-associated lymphoproliferative disorders |
| **Histiocytic and dendritic cell neoplasms** |
| Histiocytic sarcoma |
| Langerhans cell histiocytosis |
| Langerhans cell sarcoma |
| Indeterminate dendritic cell histiocytosis* |
| Interdigitating dendritic cell sarcoma* |
| ALK-positive histiocytosis* |
| Disseminated juvenile xanthogranuloma |
| Erdheim-Chester disease |
| Rosai-Dorfman-Destombes disease* |
| Follicular dendritic cell sarcoma |
| Fibroblastic reticular cell sarcoma* |
| Epstein-Barr virus–positive inflammatory follicular dendritic cell/fibroblastic reticular cell tumor* |

*Italic font* indicates provisional tumor entities.

*Changes from the 2016 WHO classification.

†These lesions are classified according to the lymphoma to which they correspond.

Pathologists also recognize a tissue-based MBL, usually as an incidental nodal finding of an infiltrate of CLL-type cells without proliferation centers in individuals without significant lymphadenopathy.[19,20] These patients usually have MBL in peripheral blood. At the other end of the CLL spectrum, the CAC emphasized the need to distinguish accelerated CLL from diffuse large B-cell (Richter) transformation, the latter containing sheets of large cells and not just expanded proliferation centers.[21] The recent identification of reversible proliferations of sheets of large cells (Richter-like) in patients in which ibrutinib has been temporarily interrupted is a challenging situation to be considered in the interpretation of disease in such patients.[22,23] These patients should be managed with caution and reevaluated after the reintroduction of ibrutinib.

The criteria for the diagnosis of B-cell prolymphocytic leukemia were also reviewed, and the group considered that the entity needs to be recognized only after rigorous exclusion of other lymphoid neoplasms, particularly transformation from CLL, mantle cell lymphoma (MCL), or splenic marginal zone lymphoma (SMZL).

## Splenic marginal zone lymphoma

SMZL cannot be diagnosed on the basis of the extent of bone marrow or peripheral blood involvement alone. The presence of a clonal B-cell population in these locations with a phenotype

Downloaded from ashpublications.org/blood/article-pdf/140/11/1229/1921035/bloodbld2022015851c.pdf by guest on 15 September 2026

consistent with MZL requires clinical or imaging evidence of splenic involvement for the diagnosis of an overt lymphoma. Distinction of SMZL from splenic diffuse red pulp small B-cell lymphoma requires evaluation of splenic histology. Next-generation sequencing (NGS) studies have identified recurrent mutations, including *KLF2*, *NOTCH2*, *TNFAIP3*, *KMT2D*, and *TP53* among others.[24-26] Sequencing studies may support the diagnosis of SMZL, but the overlap with other entities makes NGS profiles inadequate for establishing a diagnosis in isolation. Recent data have described genetically defined subsets of SMZL with prognostic differences.[27] *MYD88* mutations remain valuable in the differential diagnosis of SMZL vs lymphoplasmacytic lymphoma (LPL).

## Lymphoplasmacytic lymphoma and immunoglobulin M monoclonal gammopathy of undetermined significance

The diagnostic criteria for LPL have been refined from the revised fourth edition of the WHO classification.[7] In keeping with the diagnostic criteria proposed by the International Workshop on Waldenström's Macroglobulinemia, a diagnosis of LPL may be rendered in patients with abnormal lymphoplasmacytic aggregates in the bone marrow and evidence of clonal B cells and plasma cells, even when the aggregates represent <10% of cellularity of the trephine biopsy.[28] Molecular studies for *MYD88* and *CXCR4* mutations are strongly encouraged in the workup of suspected LPL. *MYD88* mutations in the Toll-interleukin-1R resistance (TIR) domain are found in >90% of LPLs; the L265P variant is predominantly present, although non-L265P variants may rarely be present. Although *MYD88* mutations are not specific, they help with the diagnosis of LPLs in an appropriate clinicopathologic context.[29-31] A small percentage of patients with LPL have *MYD88* wild-type with alternative mutations downstream of MYD88 in the NFKB signaling pathway.[32,33] Absence of an *MYD88* mutation therefore does not completely exclude the diagnosis of LPL. *CXCR4* mutations are identified in up to 40% of patients with LPL, particularly LPL with nonsense variants, which have been associated with symptomatic hyperviscosity and resistance to ibrutinib therapy.[34-36] However, this effect is complex and requires further research as treatment options expand.

The diagnosis of immunoglobulin M monoclonal gammopathy of undetermined significance (IgM MGUS) is established in patients who have IgM paraprotein with <10% bone marrow plasma cells and who lack lymphoplasmacytic B-cell aggregates sufficient for a diagnosis of LPL.[29,37] Two subtypes of IgM MGUS are now further distinguished[32]: IgM MGUS of plasma cell type and IgM MGUS, not otherwise specified (NOS). The rare IgM MGUS of plasma cell type is considered a precursor of MM and is defined as showing clonal plasma cells without a detectable B-cell component and with wild-type *MYD88*. This category also includes patients with t(11;14)(q13;q32) or other cytogenetic abnormalities typical of MM. The remaining patients with IgM MGUS, NOS include all those with an *MYD88* mutation, those with detectable monotypic or monoclonal B cells but without abnormal lymphoplasmacytic aggregates diagnostic of LPL, and those who lack evidence of other small B-cell neoplasms. Routine fluorescence in situ hybridization (FISH) studies and *MYD88* mutation analysis are recommended to identify the rare tumors more likely to progress to MM rather than LPL or other B-cell neoplasms.

Primary cold agglutinin disease is recognized as a new diagnostic category, distinct from LPL or IgM MGUS. This disease lacks the *MYD88* L265P mutation but displays recurrent trisomies of chromosomes 3, 12, and 18 and recurrent mutations in *KMT2D* and *CARD11*.[38-40]

## Plasma cell neoplasms

Clinicians participating in the CAC strongly supported the term "multiple myeloma" over "plasma cell myeloma." MM is a genetically heterogeneous disease with 2 main groups defined by cytogenetics. Specifically, 40% to 50% of patients show recurrent IGH translocations with a variety of partner genes, whereas up to 55% of patients with MM lack IGH translocations and are characterized by hyperdiploidy, with a small subset of patients not falling into either category.[41,42] These primary genetic abnormalities are present in precursor conditions and persist throughout the disease course. They are associated with prognosis, treatment response, and other clinical and phenotypic features and have a strong correlation with the gene expression profile (GEP).[41,43-45] Therefore, MM can be formally divided into mutually exclusive diagnostic groups: (1) MM, NOS and (2) MM with recurrent genetic abnormalities, including MM with *CCND* family translocations, MM with *MAF* family translocation, MM with *NSD2* translocation, and MM with hyperdiploidy. Detection of t(4;14), t(14;16), and secondary changes, including del(17p), amp1q, and del(1p) identifies patients with high-risk disease.[46-48] Currently, interphase FISH is the technique of choice for cytogenetic characterization, and consensus FISH panels for MM have been published.[47] The role of mutational analysis requires further study, particularly given the frequent subclonal evolution and spatial heterogeneity in MM.[45,49-51]

MGUS of the non-IgM type is a virtually universal precursor to MM.[52] Although most patients with MGUS are asymptomatic, several conditions associated with clonal Ig secretion in the absence of overt malignancy have been recognized and have been termed "monoclonal gammopathy of renal significance (MGRS) or monoclonal gammopathy of clinical significance (MGCS)."[53,54] However, these do not represent separate disease entities; instead, they are descriptive terms that can be added as a clinical feature to the underlying diagnosis (eg, MGUS).

Smoldering or asymptomatic MM, defined as lacking features of active MM (SLiM CRAB criteria: SLiM: 60% or more clonal plasma cells, light chains, and magnetic resonance imaging; CRAB: increased calcium level, renal dysfunction, anemia, and destructive bone lesions) or amyloid light chain (AL) amyloidosis,[37] exhibits broad variability in progression to active MM. Risk stratification with models proposed for this situation should be used to select patients suited for early therapeutic intervention.[55]

Solitary plasmacytomas of bone and primary extramedullary plasmacytomas are plasma cell neoplasms with low to moderate risk for progression to MM.[56,57] Because minimal marrow involvement detected by flow cytometry (ie, clonal plasma cells present but <10%) is of major prognostic importance, particularly with solitary plasmacytomas of bone, this feature should be incorporated into the diagnosis of these entities.[56,58]

For clarity, primary amyloidosis should be termed "Ig light chain (AL) amyloidosis" and needs to be separated from localized AL amyloidosis (also termed "amyloid tumor"), a rare disorder with

Downloaded from ashpublications.org/blood/article-pdf/140/11/1229/1921035/bloodbld2022015851c.pdf by guest on 15 September 2026

**Table 2. Highlights of changes in the International Consensus Classification of small B-cell lymphoid neoplasms**

| Entity/category | Change |
|---|---|
| Chronic lymphocytic leukemia | Need to evaluate IGHV mutational status and *TP53*/17p alterations at the time of treatment. Reversible Richter-like proliferations in patients in which a BTK inhibitor has been interrupted must be distinguished from diffuse large B-cell lymphoma transformation. |
| Lymphoplasmacytic lymphoma (Waldenström macroglobulinemia) | Diagnosis may be made with lymphoplasmacytic aggregates in trephine biopsies <10% of cellularity with evidence of clonal B cells and plasma cells. Molecular studies for *MYD88*$^{L265P}$ and *CXCR4* mutations are strongly encouraged in the workup of suspected lymphoplasmacytic lymphoma. |
| MGUS | Two types of IgM MGUS are recognized: a plasma cell type and an NOS type. Monoclonal gammopathy of renal significance and monoclonal gammopathy of clinical significance are recognized but they do not represent separate disease entities. |
| Primary cold agglutinin disease | Recognized as a new distinct entity. *MYD88*$^{L265P}$ mutation is absent. |
| Multiple myeloma | The term "multiple myeloma" is preferred over "plasma cell myeloma." Multiple myeloma should be subclassified into 1 of 4 mutually exclusive cytogenetic groups ("multiple myeloma with recurrent cytogenetic abnormalities") or designated as NOS. |
| Solitary plasmacytoma of bone and extraosseous plasmacytoma | Minimal bone marrow involvement by clonal plasma cells is of major prognostic importance, particularly with solitary plasmacytomas of bone. |
| Primary cutaneous marginal zone lymphoproliferative disorder | Now recognized as a distinct entity to be segregated from other mucosa-associated lymphoid tissue lymphomas and designated as a lymphoproliferative disorder. Two subtypes are distinguished largely based on expression of either class-switched Ig or IgM. |
| Follicular lymphoma | Cytological grades are maintained. In follicular lymphoma grade 3, *BCL2* rearrangement and CD10 positivity both favor grade 3A over grade 3B. Patients with follicular lymphoma grade 3B with IRF4/MUM1 expression should be evaluated for *IRF4* alteration, especially younger patients. Routine molecular testing is currently not required, but it can be useful in selected patients for differential diagnosis and specific therapeutic options (eg, EZH2 inhibitors). |
| *BCL2*-R negative, *CD23*-positive follicle center lymphoma | Recognized as a specific form of follicle center lymphoma, frequently but not always with a diffuse pattern, pelvic/inguinal location, and common *STAT6* mutations. |
| Primary cutaneous follicle center lymphoma | Molecular and cytogenetic studies further support its segregation from other follicular lymphomas and may help predict subsequent extracutaneous dissemination. |
| Testicular follicular lymphoma | Recognized as a distinct form of follicular lymphoma in young boys. |
| Large B-cell lymphoma with *IRF4* rearrangement | Upgraded to a definite entity. Occasionally identified in adults, and it has features similar to those in children. Definition does not include aggressive B-cell lymphomas with *IRF4* rearrangements that may be associated with *BCL2*-R or *MYC*-R. |
| Mantle cell lymphoma | Definition is expanded to include genetic variants with *CCND2* and *CCND3* rearrangements with IG genes in otherwise typical mantle cell lymphoma. Aggressive B-cell lymphomas with secondary *CCND1* rearrangements should not be diagnosed as mantle cell lymphoma. |

excellent prognosis and rare progression to systemic AL amyloidosis.[59-61]

## Marginal zone lymphomas

There is no indication for separately classifying extranodal MZLs of mucosa-associated lymphoid tissue (MALT lymphoma) based on site of presentation except for cutaneous MZL, which is now designated separately as a lymphoproliferative disorder (see "Cutaneous lymphomas" below). The clinical management approach, however, may differ between anatomic sites (eg, gastric MALT). In nodal MZL, significant heterogeneity is recognized, but there is no consensus on further alterations to the diagnostic criteria. The diagnosis of large-cell transformation of MZL should continue to rest on the finding of diffuse sheets of large cells.

## Follicular lymphoma

For follicular lymphoma (FL), the consensus was to retain morphologic grading (grades 1-2, 3A, and 3B) according to previously described criteria.[7] Whether patients with grade 3A have a more adverse prognosis and deserve different management than those with grades 1 to 2 remains debatable[62-64] and needs to be re-evaluated, given evolving non-cytotoxic therapeutic approaches. Grade 3B clearly differs in its clinical behavior, and patients are usually managed similarly to those with diffuse large B-cell lymphoma (DLBCL).[65,66] Hence, distinction between grade 3A and 3B is critical, and some higher-grade lesions are difficult to classify.[67] The consensus was that the presence of *BCL2* rearranged (*BCL2*-R) and CD10 positivity (detectable by FISH) both favor FL grade 3A (Figure 1). In addition, patients with grade 3B-expressing IRF4/MUM1 should be evaluated for *IRF4* alterations,[68,69] especially in younger patients. Routine screening for *MYC*-R is not recommended for detecting the rare patients with FL who carry both *BCL2*-R and *MYC*-R, although those patients might have a more aggressive outcome.[70-73] Proliferation index using Ki-67 staining can be specified, but it has uncertain clinical significance in isolation[74] and is not required for grading. Routine molecular testing is

Downloaded from ashpublications.org/blood/article-pdf/140/11/1229/1921035/bloodbld2022015851c.pdf by guest on 15 September 2026

**Table 3. Highlights of changes in the International Consensus Classification of aggressive B-cell lymphomas**

| | |
|---|---|
| Diffuse large B-cell lymphoma, NOS | The cell-of-origin designation in diffuse large B-cell lymphoma, NOS should be maintained, but it is considered insufficient to fully capture the biological complexity of these tumors. Molecular profiling studies have identified 5 to 7 new functional genetic subgroups of diffuse large B-cell lymphoma that may provide more precise patient stratification in the future. |
| *Large B-cell lymphoma with 11q aberration* | This term replaces Burkitt-like lymphoma with 11q aberration, and the entity is still considered provisional. Molecular studies indicate that it is closer to diffuse large B-cell lymphoma than to Burkitt lymphoma. |
| Nodular lymphocyte predominant B-cell lymphoma | This term replaces nodular lymphocyte-predominant Hodgkin lymphoma, recognizing major biological and clinical differences from classic Hodgkin lymphoma. Close relationship to T-cell/histiocyte-rich large B-cell lymphoma is emphasized. |
| Primary diffuse large B-cell lymphoma of the testis | Now recognized as a specific entity closely related to primary diffuse large B-cell lymphoma of the central nervous system. Most patients share molecular and cytogenetic features of the MCD/C5[131-134] subgroup of diffuse large B-cell lymphoma, similar to some other primary extranodal large B-cell lymphomas of the activated B-cell–like subtype. |
| *HHV-8 and Epstein-Barr virus–negative primary effusion-based lymphoma* | Recognized as a provisional entity frequently associated with fluid overload. Patients who conform to other well-defined lymphomas should not be included. |
| Epstein-Barr virus–positive mucocutaneous ulcer | Now recognized as a definite entity, and diagnostic criteria have been refined. |
| Epstein-Barr virus–positive diffuse large B-cell lymphoma, NOS | Tumors are morphologically heterogeneous, but the distinction between polymorphic and monomorphic does not have prognostic significance in the elderly. The T-cell/histiocyte-rich large B-cell lymphoma–like pattern, more common in younger patients (younger than age 45 years), is distinct from what has been termed polymorphic. |
| Lymphomatoid granulomatosis | Generally diagnosed in the absence of known immunodeficiency and, per definition, requires pulmonary involvement. Isolated central nervous system or gastrointestinal tract involvement by an Epstein-Barr virus–positive lesion resembling lymphomatoid granulomatosis is usually associated with immunodeficiency and Epstein-Barr virus latency III. These patients should be classified as Epstein-Barr virus–positive B-cell lymphoproliferative disorder or Epstein-Barr virus–positive diffuse large B-cell lymphoma, NOS and not as lymphomatoid granulomatosis. |
| *Epstein-Barr virus–positive polymorphic B-cell lymphoproliferative disorder, NOS* | A term used for B-cell proliferations with or without known immunodeficiency when the morphologic changes do not fulfill the criteria of a well-defined Epstein-Barr virus–positive lymphoma. In patients with focal Epstein-Barr virus–positive B cells and preserved lymph node architecture, the term "EBV reactivation" is preferred. |
| Primary effusion lymphoma and extracavitary primary effusion lymphoma | In patients with Epstein-Barr virus–negative extracavitary lymphoma, a diagnosis of HHV-8–positive diffuse large B-cell lymphoma, NOS is preferred, particularly if the tumor is IgM lambda positive. |
| Burkitt lymphoma | Neoplasms with a precursor B-cell phenotype and *MYC* rearrangement will be called B-lymphoblastic leukemia/lymphoma with *MYC* rearrangement rather than Burkitt leukemia or lymphoma. |
| High-grade B-cell lymphoma with *MYC* and *BCL2* rearrangement | The category is redefined to exclude patients with only *MYC* and *BCL6* rearrangements. Some neoplasms may express terminal deoxynucleotide transferase without being considered a B-lymphoblastic neoplasm. |
| *High-grade B-cell lymphoma with MYC and BCL6 rearrangements* | With the change in the definition of high-grade B-cell lymphoma with *MYC* and *BCL2* rearrangements, this provisional category was added. |
| Mediastinal gray-zone lymphoma | Criteria for distinction from classic Hodgkin lymphoma have been refined. Clinical and genomic data indicate that most non-mediastinal gray-zone lymphomas are distinct from mediastinal gray-zone lymphoma; thus, patients with extra-mediastinal disease should be diagnosed as having diffuse large B-cell lymphoma, NOS. |

*Italic font* indicates provisional tumor entities.

currently unnecessary, but it can be useful in selected patients for differential diagnosis (eg, pediatric-type FL, plasmacytic differentiation, MZL, *BCL2*-R–negative patients). Detection of *EZH2* mutations provides additional information when treatment with an *EZH2* inhibitor is being considered.[75] Use of an NGS panel for clinical prognostication such as the m7-FLIPI (mutation status of 7 genes [*EZH2*, *ARID1A*, *MEF2B*, *EP300*, *FOXO1*, *CREBBP*, and *CARD11*] along with the FL International Prognostic Index)[76] improves risk stratification but remains investigational.

Nodal FL negative for *BCL2*-R is heterogeneous, both genetically and clinically.[77-79] The specific subtype of *BCL2*-R–negative, CD23$^{+}$ follicle center lymphoma was proposed as a provisional new entity based on correlation of CD23 with *STAT6* mutation,

Downloaded from ashpublications.org/blood/article-pdf/140/11/1229/1921035/bloodbld2022015851c.pdf by guest on 15 September 2026

low-stage disease, and often a predominant diffuse growth pattern. This variant typically presents with localized inguinal involvement.

Pediatric-type FL remains a clearly defined entity with recurrent genomic alterations and excellent prognosis with conservative management.[80-83] Distinguishing pediatric-type FL from FL grade 3B remains critical. Recent work has suggested that pediatric-type FL may be related to the pediatric variant of MZL, which had been listed as provisional in the classification.[84] Testicular FL, recognized as a new distinct entity of FL in young boys, shares pathological and clinical features with pediatric-type FL, because most patients can be managed conservatively, without systemic chemotherapy.[85,86]

Large B-cell lymphoma with *IRF4* rearrangement, upgraded now to a definite entity, is most common in children and young adults and usually has at least a partially follicular growth pattern.[69] However, the same disease is not commonly seen in adults. FISH for *IRF4*-R must be performed for diagnosis. Patients lacking demonstrable rearrangements should have evidence of either IGH or IGK/IGL breaks. Detection of *IRF4* mutation may support the diagnosis.[69] *IRF4*-R can occur in other aggressive B-cell lymphomas associated with *BCL2*-R or *MYC*-R, mainly in adults, and in this context, it is not specific for the entity.[69]

## Mantle cell lymphoma

The *CCND1* translocation with IG genes is the genetic hallmark of MCL. Some patients with the same morphology, phenotype, and SOX11 expression as that found in conventional MCL lack *CCND1* rearrangements but have (sometimes cryptic) *CCND2* or *CCND3* translocations.[87-90] These patients must also be diagnosed as having MCL. *CCND2* and *CCND3* translocations by FISH or messenger RNA overexpression should be demonstrated in these patients, because immunohistochemistry for these cyclins is not discriminant.[91] The presence of t(11;14)(q13;q32) may also be a secondary event in the progression of some mature B-cell lymphomas. Patients with that abnormality should not be diagnosed as having MCL.[92-97] *CCND1* rearrangement has also been found in large B-cell lymphomas associated with *MYC* and *BCL2* or *BCL6* translocations. The negativity of CD5 and SOX11 and the presence of mutations uncommon in MCL favor the diagnosis of DLBCL over MCL.[96] Conversely, *MYC* may be rearranged in bona fide MCL, usually with blastoid or pleomorphic morphology and aggressive behavior.[98-101] Using the term "double-hit" (DH) MCL for these patients is not recommended and those patients should not be included in the high-grade B-cell lymphoma (HGBCL) category. Some of these patients may be SOX11 negative or express terminal deoxynucleotide transferase (TdT).[100] Genomic studies may help in the differential diagnosis with other lymphomas.

MCLs with more aggressive or indolent behavior need to be identified. The unfavorable outcome of blastoid or pleomorphic variants, high Ki-67 (≥30%), and *TP53* deletions or mutations have been extensively confirmed and should be evaluated, preferably at diagnosis, in all patients.[102-106] Determination of the Ki-67 proliferative index is currently based on visual inspection according to previously described criteria.[105] Whether the evaluation of proliferation or other quantitative parameters suggested in this ICC proposal will benefit from quantitative flow cytometry, RNA technologies, or computer-assisted image analysis in clinical practice will require standardization and validation studies. Genomic complexity is also associated with worse outcome, but further studies are needed before incorporation into clinical practice.[99,107,108] At the other end of the spectrum, most leukemic non-nodal MCLs (nnMCLs) are clinically indolent, although the acquisition of *TP53* alterations and genomic complexity confer an adverse prognosis. MCL in these patients is considered a subtype of MCL because t(11;14) is acquired in precursor B cells as in conventional MCL.[99,107,108] Recognition of nnMCL relies on a combination of clinical and pathological characteristics. Features that favor this diagnosis are non-nodal or limited nodal (≤3 cm) presentation, negative or low SOX11 expression (<10%), CD23 and CD200 positivity, and hypermutated IGHV (<98%).[108-112] Absence of *ATM* mutations or deletions and *CCND1* mutations are also features of nnMCL.[99] MCL with isolated gastrointestinal involvement usually has an indolent behavior and should be clinically recognized, although more data are needed to determine significance.[113-115]

## Diffuse large B-cell lymphomas

DLBCL, NOS encompasses all patients with nodal and extranodal large B-cell lymphoma that do not belong to a specific diagnostic category (Table 1). It is not a single disease but a collection of morphologically, genetically, and clinically different diseases. Therefore, it can be subdivided into morphologic variants, phenotypic variants, and molecular or genetic categories. The role of morphologic variants (centroblastic, immunoblastic, and anaplastic) and phenotypic variants (DLBCL, CD5$^+$,[116-119] and DLBCL double expressor [MYC/BCL2])[120-122] should be deemphasized. These variants have (weak) adverse prognostic impact and do not reflect true biological subgroups but rather represent the end results of different biological pathways. The conference considered that at this time, the cell-of-origin designation in DLBCL, NOS[123,124] should be maintained. The cell-of-origin distinction is a basic biological division of DLBCL with prognostic impact that can be widely deployed using either IHC (germinal center B-cell–like [GCB] and non-GCB patients) or gene expression (GCB, activated B-cell–like [ABC], and unclassified patients) algorithms. However, the largely disappointing results of trials of first-line treatment of DLBCL, NOS that incorporated targeted agents and use cell-of-origin for patient selection underscore the lack of sufficient detail for this binary classification and highlight the importance of a more molecularly based approach.[125-130] Recently, molecular and cytogenetic profiling studies have independently identified 5 to 7 new functional genetic subgroups of DLBCL, which strongly emphasizes the validity of this concept but fails to classify all patients (Figure 2).[131-134] A combination of cell-of-origin and molecular subclassification may provide more precise patient stratification for developing future clinical trials.[135] Overall, cell-of-origin is retained for the present time with the expectation that transition to a molecular genetic classification will be feasible in the near future.

An intensely debated but ultimately unresolved issue is whether an umbrella term such as "extranodal lymphoma ABC (non-GCB) type" should be created for (some) extranodal DLBCLs. This would primarily (but not exclusively) include patients with DLBCL that arises in immune-privileged sites such as primary

Downloaded from ashpublications.org/blood/article-pdf/140/11/1229/1921035/bloodbld2022015851c.pdf by guest on 15 September 2026

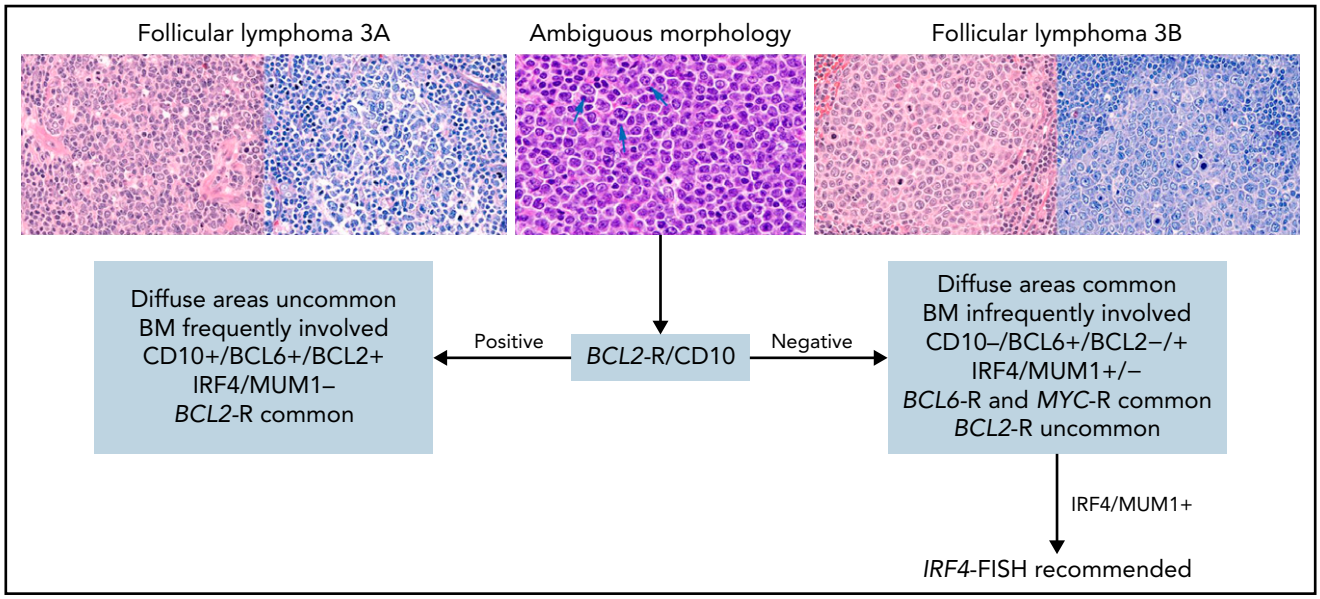


**Figure 1. Suggested diagnostic studies in FL grade 3.** Upper left: Cells from FL grade 3A are shown with hematoxylin and eosin (H&E) and Giemsa stains. Note the admixture of centrocytes and centroblasts (>15 per high power field) highlighted in the Giemsa stain. Upper right: Cells from FL grade 3B are shown with H&E and Giemsa stains. The follicles are composed of sheets of centroblasts with open chromatin, several nucleoli, and abundant basophilic cytoplasm highlighted with the Giemsa stain. Upper middle: Cells from FL with ambiguous morphology are shown. They are medium-size with open chromatin but inconspicuous nucleoli unlike centroblasts (arrows) and without the cytologic features of centrocytes. With ambiguous morphology (blue arrow), the presence of *BCL2* rearrangement and/or CD10 expression favors the diagnosis of FL grade 3A; if both are absent, a diagnosis of FL grade 3B is favored. In patients who have FL grade 3B with IRF4/MUM1 expression, *IRF4*-FISH analysis is recommended to exclude the diagnosis of large B-cell lymphoma with *IRF4* rearrangement. Original magnification ×400. BM, bone marrow.

central nervous system lymphoma (PCNSL) and primary DLBCL of the testis but possibly also primary cutaneous DLBCL, leg type, primary breast type, intravascular large B-cell lymphoma, and primary adrenal lymphomas. The rationale is that most of the lymphomas in these locations are non-GCB/non-ABC type, share biology, and seem to display common molecular features such as the high prevalence of *MYD88*$^{L265P}$ and *CD79B* mutations that characterize the DLBCL MCD/C5 genetic subgroup (Figure 2).[135-140] In particular, PCNSL and primary DLBCL of the testis share both clinical and molecular features, and for this reason, primary DLBCL of the testis is now considered a distinct entity (Tables 1 and 2). Although grouping the extranodal lymphomas arising in immune-privileged sites certainly is a reasonable proposal, there are also many caveats, including the fact that particularly in some anatomic sites, these lymphomas are heterogeneous, and in many settings, the pathologist may have incomplete data regarding the presence of other sites of disease. In the end, although many participants were inclined to group several of the extranodal DLBCL entities and variants, the majority felt that such a subcategorization of DLBCL is premature, and recognition of specific entities will be better captured by upcoming molecular categorization integrated with more traditional criteria.

## Provisional subtypes of large B-cell lymphoma

The 2016 WHO classification recognized the provisional entity, Burkitt-like lymphoma (BLL) with 11q aberration, identified originally as a lesion clinically and pathologically resembling Burkitt lymphoma (BL) but lacking *MYC*-R. The patients are more frequently children and young adults with a good prognosis. Subsequent studies have demonstrated the morphology and phenotype of these tumors to be more variable than originally described, including patients with mainly centroblastic-type large cells.[141-143] Importantly, genetic studies also suggest the disease is distinct from BL and is closer to conventional DLBCL with GCB derivation harboring more complex karyotypes and the absence of typical BL mutations.[141-145] This provisional entity has now been renamed "large B-cell lymphoma with 11q aberration" (Figure 3). Chromosome 11q gains and losses typical of patients with this abnormality can be identified by using FISH strategies. Although some studies suggest that only 11q loss may be acceptable, more information is needed before a strong recommendation can be made. Chromosomal microarray is required if FISH is equivocal for the typical pattern of gains and losses.[141]

"HHV-8 and EBV-negative primary effusion-based lymphoma" is a new provisional entity recognized on the basis of unifying features that include presentation in elderly HIV-negative patients with medical conditions that lead to fluid overload, which suggests chronic serosal stimulation in pathogenesis. About 60% of the patients have been reported in Japan, and they often have a history of hepatitis C infection.[146-148] These patients usually have a good prognosis with reported spontaneous regression or cure with drainage alone. Most tumors exibit centroblastic or immunoblastic morphology and express at least 1 B-cell marker. Other HHV-8–negative effusion-based lymphomas occur and are biologically and clinically heterogeneous. These should be classified as one of the well-defined lymphomas presenting as an effusion.

## Large B-cell lymphoproliferative disorders and viral agents

EBV-positive polymorphic B-cell LPD, NOS is a term used for EBV-positive B-cell proliferations with or without known immunodeficiency that cannot be more precisely categorized. The term

Downloaded from ashpublications.org/blood/article-pdf/140/11/1229/1921035/bloodbld2022015851c.pdf by guest on 15 September 2026

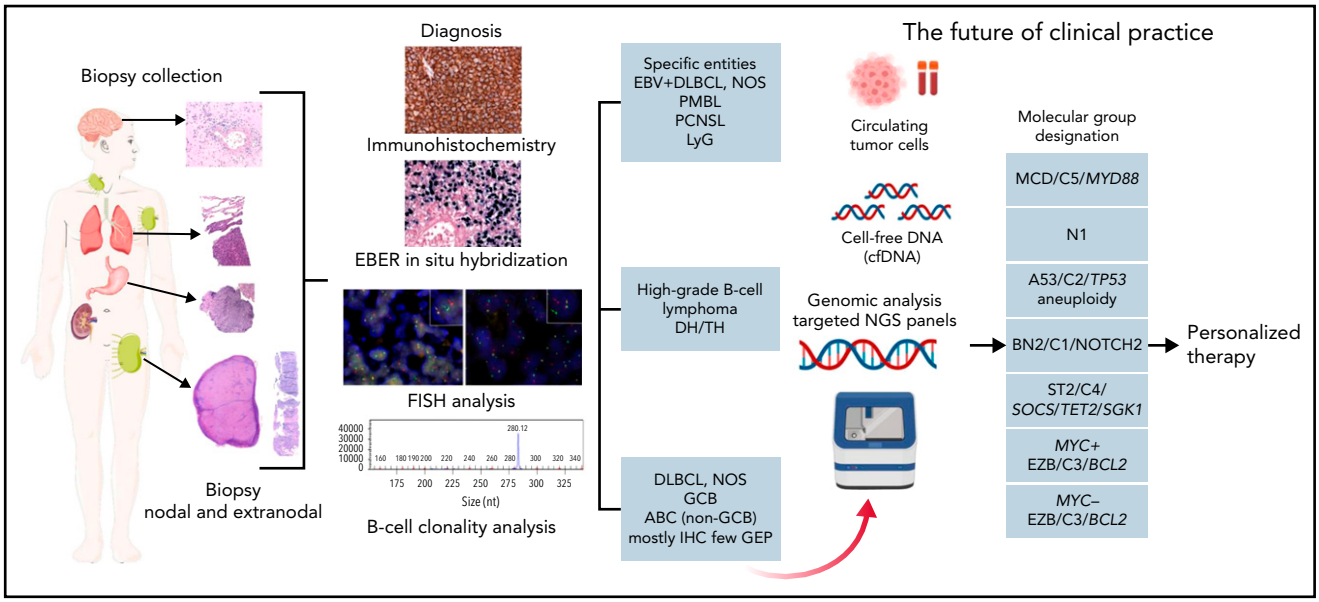


**Figure 2. Algorithm for the diagnostic workup of aggressive B-cell lymphomas.** The current algorithm for diagnosing aggressive large B-cell lymphomas starts with a biopsy collection from a lymph node (excision or needle biopsy) or a biopsy of an extranodal site. The diagnosis of the different lymphoma entities is based on a combination of morphology, immunophenotype, EBER in situ hybridization, FISH analysis, and B-cell clonality analysis. Advances in the understanding of DLBCL herald a transition to a molecular genetic classification (red arrow). This genetic classification is based on mutational profile, somatic copy number alterations, and structural variants. The depicted molecular subtypes were identified in 3 different studies indicating that these subgroups reflect true biological differences.[131,132,134] On the basis of these molecular studies, a predictor model was developed that dissects the cell-of-origin and stratifies further the molecular classification into 7 genetic subtypes with apparently clinical relevance.[133] The acronyms indicate the names given in the different studies to the same identified biological group.

should be reserved for patients with altered lymph node architecture and a polymorphic infiltrate that do not fulfill criteria for the diagnosis of lymphoma or there is uncertainty because of a small size or low-quality biopsy.[149,150] EBV-positive B-cell proliferations should be classified as lymphoma if the criteria of a well-defined EBV-associated lymphoma are fulfilled (eg, EBV-positive DLBCL, NOS, and plasmablastic lymphoma). In tissues with low to modest numbers of EBV-positive B cells without distortion of the nodal architecture, the term "EBV reactivation" is preferred. EBNA2 immunostaining is recommended in this or other clinical settings because it supports EBV latency pattern III, which suggests an underlying immunodeficiency. It is negative in most EBV-positive tumors in otherwise healthy people.

EBV-positive DLBCL, NOS, is an aggressive lymphoma that can present over a wide age range; however, patients younger than age 45 years have a better prognosis.[151-153] By definition, >80% of the malignant cells should express EBER.[152,154,155] The morphology is variable. A T-cell/histiocyte-rich large B-cell lymphoma-like pattern is frequently seen in younger patients and is associated with a better prognosis. In adults, the pattern may be monomorphic or polymorphic, but these patterns do not have prognostic impact.[152,154-156] The differential diagnosis with EBV-positive classic Hodgkin lymphoma (CHL) can be challenging; however, expression of B-cell markers in >50% of the tumor cells, extranodal presentation, and/or EBV latency III favors the diagnosis of EBV-positive DLBCL, NOS. Extended B-cell antibody panels are critical in this setting.[157] DLBCL associated with chronic inflammation and fibrin-associated DLBCL remain discrete entities, separate from EBV-positive DLBCL, NOS.

"EBV-positive mucocutaneous ulcer" was introduced in the 2016 WHO classification as a provisional entity,[5] but it is now considered a definite entity.[149,156,158-160] These are solitary lesions, usually in the oropharyngeal mucosa. Cutaneous and gastrointestinal presentations are usually associated with iatrogenic immunosuppression. In patients with ≥2 skin lesions, the term "EBV-positive B-cell polymorphic LPD," or when appropriate, "EBV-positive DLBCL, NOS," or other specific type of EBV-positive lymphoma or LPD is preferred.[160,161]

Lymphomatoid granulomatosis (LyG) is a rare angiocentric and angiodestructive LPD composed of a variable number of EBV-positive B cells admixed with numerous reactive T cells. Pulmonary involvement is required for the diagnosis.[162] Although the disease is well defined, there are significant overlapping features with other immunodeficiency-related EBV-positive B-cell LPDs.[162,163] Isolated central nervous system (CNS) or gastrointestinal tract involvement by an EBV-positive lesion resembling LyG is observed usually in the context of known causes of defective immune surveillance (EBV latency III).[164,165] In this scenario, the diagnosis of EBV-positive polymorphic B-cell LPD or EBV-positive DLBCL, NOS should be rendered.

HHV-8–associated lymphoproliferations include multicentric Castleman disease, HHV-8 germinotropic LPD, HHV-8–positive DLBCL, NOS, primary effusion lymphoma (PEL), and extracavitary PEL.[166] There are significant overlapping features among these disorders.[166,167] PEL and extracavitary PEL in HIV-positive patients are usually HHV-8 positive and EBV positive; however, in elderly HIV-negative individuals, EBV is usually negative.[166,168-170] In extracavitary presentations, the diagnosis of HHV-8–positive DLBCL, NOS should be favored in EBV-negative patients with cytoplasmic IgM lambda and/or associated with multicentric Castleman disease.[171]

Downloaded from ashpublications.org/blood/article-pdf/140/11/1229/1921035/bloodbld2022015851c.pdf by guest on 15 September 2026

**Table 4. Highlights of changes in the International Consensus Classification of mature T-cell and NK-cell neoplasms and histiocytic tumors**

| | |
|---|---|
| Hydroa vacciniforme lymphoproliferative disorder | This term replaces the previous hydroa vacciniforme-like lymphoproliferative disorder; 2 forms are recognized: classic and systemic. The classic form is indolent, self-limited, and more common in whites. The systemic form is severe and includes fever, lymphadenopathy, and often liver involvement, and it is more common in Asians and Latin Americans. Treatment is similar to that for chronic active Epstein-Barr virus disease. |
| Chronic active Epstein-Barr virus disease | This term replaces chronic active Epstein-Barr virus infection and is restricted to patients who have the T-cell and NK-cell phenotype; B-cell patients are excluded. Mutations in *DDX3X* and *KMT2D* indicate the neoplastic nature of the disease. |
| *Primary nodal Epstein-Barr virus–positive T-cell/NK-cell lymphoma* | Introduced in the 2017 WHO classification as a variant of peripheral T-cell lymphoma, NOS; it is now considered a provisional entity. |
| Type II refractory celiac disease* | Accepted as a precursor of enteropathy-associated T-cell lymphoma and has therefore been added to the classification. |
| Indolent clonal T-cell lymphoproliferative disorder of the gastrointestinal tract | Considered a definite entity. The name was changed to acknowledge its monoclonal nature. It may have neoplastic-type gene mutations and rearrangements and may progress to more aggressive disease. |
| Indolent NK-cell lymphoproliferative disorder of the gastrointestinal tract | Mutational studies provide evidence for the neoplastic origin. The term replaces both NK-cell enteropathy and lymphomatoid gastropathy. |
| Subcutaneous panniculitis-like T-cell lymphomas | Molecular studies have recognized germline *HAVCR2* mutations in a subset of patients. |
| Primary cutaneous acral $CD8^+$ T-cell lymphoproliferative disorder | Now considered a lymphoproliferative disorder rather than an overt lymphoma. |
| Follicular helper T-cell lymphoma (TFH lymphoma) | Considered a single entity that encompasses 3 subtypes: angioimmunoblastic-type (angioimmunoblastic T-cell lymphoma), follicular-type, and NOS. |
| ALK-negative anaplastic large cell lymphoma | *DUSP22*-R ALK anaplastic large cell lymphoma is now defined as a genetic subtype of systemic ALK-negative anaplastic large cell lymphoma. *JAK2* rearrangements or coexisting *TP63* and *DUSP22* rearrangements are rarely seen; understanding their significance requires further study. |
| Breast implant–associated anaplastic large cell lymphoma | Upgraded from a provisional to a definite entity. Use of tumor-node-metastasis staging criteria is recommended to facilitate clinical management. |
| Histiocytic and dendritic cell neoplasms | ALK-positive histiocytosis is accepted as an entity in the classification. A subset of Rosai-Dorfman-Destombes disease is identified as neoplastic based on clonal genetic alterations. |
| Epstein-Barr virus–positive inflammatory follicular dendritic cell/fibroblastic reticular cell tumor | The name of this entity has been changed. "Tumor" is preferred over "sarcoma" because of the indolent nature of these lesions. Heterogeneity in lineage is recognized. |

*Italic font* indicates provisional tumor entity.

## High-grade B-cell lymphomas

The 2016 WHO classification included 2 categories of HGBCL: HGBCL, NOS, and HGBCL with *MYC* and *BCL2* and/or *BCL6* rearrangements (DH or triple-hit [TH]).[5] HGBCL-DH now comprises 2 groups: HGBCL with *MYC* and *BCL2* rearrangements (with or without *BCL6* rearrangement) (HGBCL-DH-*BCL2*) and a new provisional entity, HBGBL with *MYC* and *BCL6* rearrangements (HGBCL-DH-*BCL6*). HGBCL-DH-*BCL2* and HGBCL-DH-*BCL6* entities continue to exclude FL, and the morphology (large-cell or high-grade cytology) should be reported (Figure 4).

Studies performed since the 2016 WHO classification support HGBCL-DH-*BCL2* as an aggressive lymphoma of GCB origin with distinct biology from other GCB-DLBCL, NOS and HGBCL-DH-*BCL6*.[172-177] It can occur in patients with or without previous FL. Data to support distinct biology in patients with HGBCL-DH-*BCL6* are less compelling[172,173]; however, it has been retained as a provisional entity to allow for continued study based on the poor outcomes seen in some studies.[175,178-181] Although pseudo-DH lymphomas (*MYC*-R with *BCL6* partner) account for up to 30% of patients with HGBCL-DH-*BCL6*,[182] strategies to identify this are not essential at this time. Neither copy number increase nor amplification of these genes is sufficient to substitute for rearrangement in these categories.[183-186] Furthermore, the significance of the *MYC* partner gene remains controversial; *MYC*-R with both IG and non-IG partners is included at present.[180,187,188]

Although HGBCL, NOS is acknowledged as a heterogeneous category, it remains in this classification as a diagnosis of exclusion for tumors which are not HGBCL-DH but which have intermediate-size cells, often with blastoid or Burkitt-like

Downloaded from ashpublications.org/blood/article-pdf/140/11/1229/1921035/bloodbld2022015851c.pdf by guest on 15 September 2026

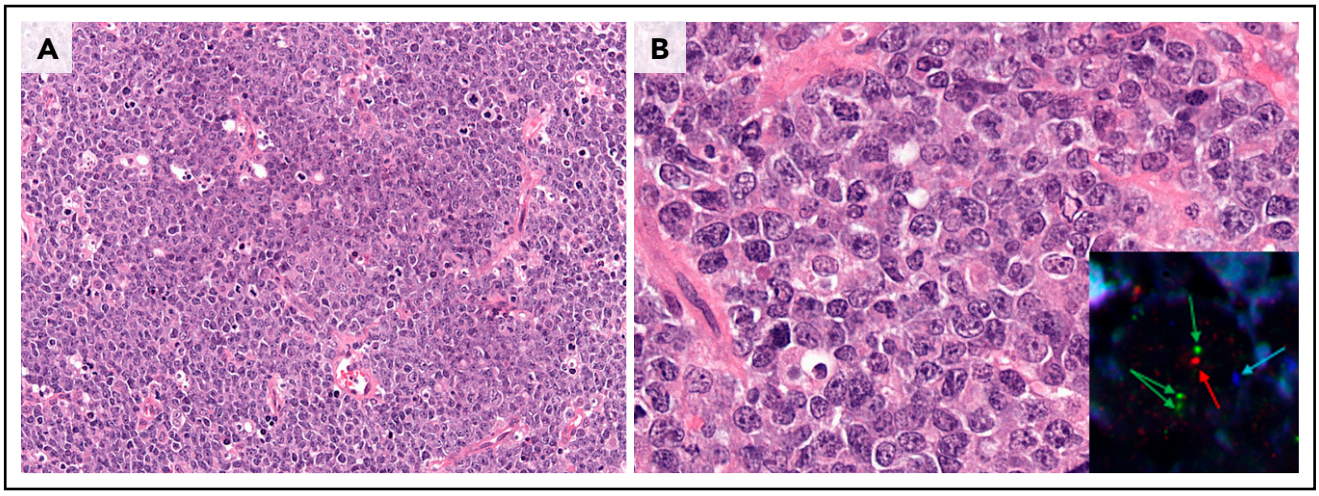


**Figure 3. Large B-cell lymphoma with 11q aberration.** (A) Low power view of large-cell morphology, abundant mitoses, and the characteristic starry-sky pattern with abundant macrophages with coarse apoptotic bodies (original magnification ×200; H&E stain). (B) Higher magnification reveals the large centroblastic morphology of the tumor cells (original magnification ×400; H&E stain). Inset: FISH analysis demonstrated the typical 11q alterations (blue, centromere; red, 11q24 loss; green, 11q23 gain; ×1000). The cytology of the cells might be medium-size to large-size cells. The morphology and mutational profile justify the change in the name of this entity (previously, Burkitt-like lymphoma with 11q aberration).

cytology (Figure 3) but cannot be classified as DLBCL or BL.[189,190] These patients are rare, and the diagnosis can be made only on well-fixed and preserved specimens because large-cell cytology must be excluded. DLBCL with starry-sky morphology and/or a high proliferation index does not merit recategorization as HGBCL, NOS.

Previously, TdT expression in HGBCL or DLBCL was sufficient to reclassify the disease in these patients as lymphoblastic leukemia/lymphoma.[7] However, the mutational landscape of TdT-positive HGBCL now supports the inclusion of this disease as a mature lymphoma with "expression of TdT" noted in the diagnostic line.[191-193] Distinction between patients with this disease and those with acute leukemia requires thorough phenotypic and genetic evaluation.[191-194]

Diagnostic criteria for BL remain largely unchanged. However, data have emerged to segregate TdT-positive patients from those with BL. These rare patients have an immature B-cell phenotype and molecular features of precursor B cells, including evidence of IG::*MYC* translocation arising from aberrant variability, diversity, and joining (VDJ) recombination, frequent lack of a productive IGH rearrangement, DNA methylation patterns similar to those in other pre–B-cell acute leukemias, and recurrent *NRAS* and *KRAS* mutations.[195] On the basis of these data, designating these patients as having B-lymphoblastic leukemia/lymphoma with *MYC*-R is appropriate to recognize their biology and allow clinicians to consider appropriate treatment options (see Arber et al in this series).[196,197]

## Hodgkin lymphomas

The CAC conference discussed key issues related to the classification of Hodgkin lymphomas and patients with borderline diagnostic criteria. The conference concluded that new terminology is warranted for nodular lymphocyte-predominant Hodgkin lymphoma (NLPHL), based on major biological and clinical differences with CHL and with close relationship to T-cell/histiocyte-rich large B-cell lymphoma.[198] The term "nodular lymphocyte predominant B-cell lymphoma" (NLPBL) was accepted by consensus. The value of identifying variant histology in NLPBL was recognized, with the suggestion that typical patients with Fan patterns A, B, and C or grade 1 be distinguished from Fan patterns D, E, and F or grade 2.[199] Patients falling within grade 2 generally show loss of a well-formed nodular pattern and increased infiltration by T cells with a reduction of background small B cells. Patients with grade 2 histology may warrant treatment for DLBCL, but clinical features should play a role in treatment decisions.[200] Rare examples of NLPBL are EBV-positive with uncertain clinical implications.[201]

The major subtypes of CHL remain unchanged. A standard immunohistochemical panel using CD30, CD15, IRF4/MUM1, PAX5, CD20, CD3, and LMP1 or EBER in situ hybridization is advised. Additional immunohistochemical or clonality studies may be warranted in the setting of atypical histological or clinical features.

A major topic of discussion related to the criteria for mediastinal gray zone lymphoma (MGZL). This term is preferred over what was previously designated "B-cell lymphoma, unclassifiable," with features intermediate between DLBCL and CHL. A diagnosis of MGZL requires both morphologic (high density of tumor cells) and immunophenotypic criteria (at least 2 B-cell markers with strong expression).[202,203] Patients with otherwise typical nodular sclerosis CHL with variable expression of CD20 are still designated as having CHL, although a close biological relationship to primary mediastinal large B-cell lymphoma remains.[204] Sequential primary mediastinal large B-cell lymphoma and nodular sclerosis CHL reinforce the concept of MGZL, because these diseases have been demonstrated to be of common clonal origin. However, clinical and genomic data indicate that most patients with non-mediastinal GZL are distinct from those with MGZL, and they should be diagnosed as having DLBCL, NOS. Finally, nearly all patients with EBV-positive DLBCL, while they may harbor admixed Hodgkin/Reed-Sternberg-like cells, differ at the genomic level from patients with MGZL and should be retained within the category of EBV-positive DLBCL.[152,205]

Downloaded from ashpublications.org/blood/article-pdf/140/11/1229/1921035/bloodbld2022015851c.pdf by guest on 15 September 2026

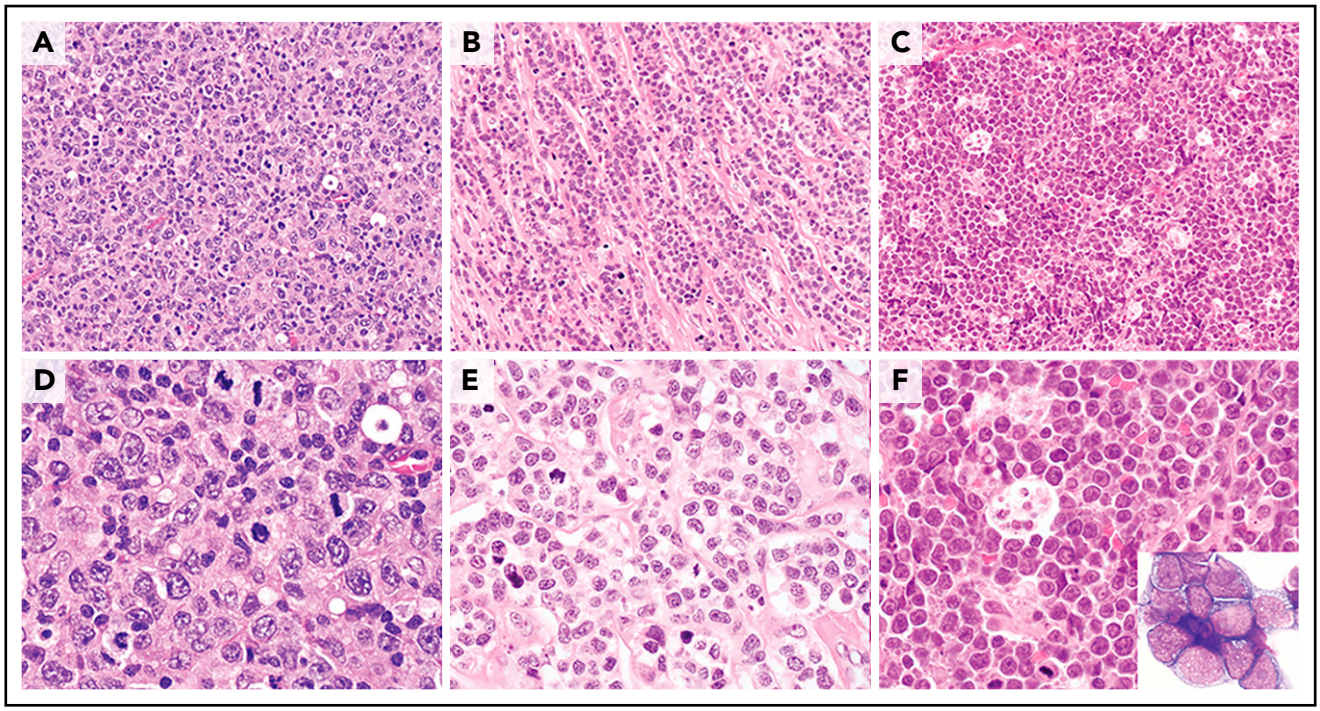


**Figure 4. Morphologic characterization of highly proliferative B-cell lymphomas.** (A-B) This DLBCL, NOS has many mitotic figures, but many of the neoplastic cells are typical large transformed cells that do not resemble either BL cells or B lymphoblasts. Chromosomal analysis showed a complex karyotype, but there was no evidence of *MYC* or *BCL2* rearrangement. (C-D) This HGBCL, NOS is composed of relatively small blastoid-appearing cells with many mitotic figures, reminiscent of a B-lymphoblastic leukemia/lymphoma. TdT was negative. It had a complex karyotype that included t(14;18)(q32;q21) and i(17)(q10). (E-F) This HGBCL with *MYC* and *BCL6* rearrangements (without evidence of IGH::*BCL2*) resembles BL with intermediate-size transformed cells and a starry-sky appearance with scattered tingible body macrophages. The cytospin (inset) demonstrated cytoplasmic vacuoles. Unlike classic BL, it was BCL2 protein positive and had only equivocal CD10 positivity. All panels were stained with H&E except for the inset stained with Wright-Giemsa stain. Original magnification ×400 for panels A, C, and E; original magnification ×1000 for panels B, D, and F and inset.

# Mature T-cell and NK-cell neoplasms

At the CAC meeting, discussion of the T-cell and NK-cell neoplasms focused on those areas in which new insights into the pathogenesis and clinical behavior have occurred. Thus, only a subset of this large and diverse group of tumors will be covered.

## EBV-related mature T-cell and NK-cell neoplasms

EBV-positive T-cell and NK-cell LPDs in children are now separated into 4 major groups: hydroa vacciniforme (HV) LPD, severe mosquito bite allergy, chronic active EBV (CAEBV) disease, and systemic EBV-positive T-cell lymphoma of childhood (Table 4). All occur with increased frequency in Asia and Latin America. HV LPD presents with skin lesions on sun-exposed areas with EBV-infected T or NK cells and very high levels of EBV DNA in blood.[7,206,207] This disease was previously referred to as hydroa vacciniforme-like LPD; however, it is now known that all HV lesions have EBV. Some patients, especially white patients, have stable disease involving only the skin (classic HV LPD)[208] whereas others, especially Asians[209] and Hispanics have concomitant systemic EBV-positive T cells or NK cells involving internal organs (systemic HV LPD).[206,210,211] This latter group eventually requires treatment similar to that for CAEBV disease.[212] CAEBV disease is a progressive disorder that lasts 3 or more months during which patients have markedly increased levels of EBV DNA in the blood and infiltration of organs by EBV-infected lymphocytes in the absence of a known immunodeficiency.[213-215] This illness was previously referred to as CAEBV infection; however, because most adults are chronically infected with EBV, the term "CAEBV disease" is preferred. Previously, CAEBV disease included EBV-infected T, NK, or B cells. Many patients with B-cell CAEBV have been diagnosed with underlying primary immunodeficiency; therefore, CAEBV should include only T- or NK-cell disease.[216] Some patients in South America present with facial edema, high levels of EBV DNA in T or NK cells in the blood, and EBV in internal organs; these patients should be classified as having CAEBV disease and not HV LPD.[217] New genetic studies have shown that CAEBV disease shares somatic mutations (eg, *DDX3X* and *KMT2D*) similar to those in T- and NK-cell lymphomas, indicating that it is a premalignant condition. Furthermore, the EBV genome harbors intragenic deletions common in various EBV-associated neoplastic disorders but not detected in reactive conditions such as infectious mononucleosis, which suggests an important role of these mutations in EBV-associated neoplasia.[218]

"Primary nodal EBV-positive T- or NK-cell lymphoma" is a rare disease introduced in the 2017 WHO classification as a variant of peripheral T-cell lymphoma (PTCL), NOS.[7] New findings have led to the designation of this lymphoma as a provisional entity.[219] It presents more commonly in elderly and/or immunodeficient patients, lacks nasal involvement, and is more often of T-cell rather than NK-cell lineage.[220,221] This lymphoma is characterized by a dismal outcome, low genomic instability, upregulation of immune pathways (checkpoint protein programmed death-ligand 1 [PD-L1]) that promote immune evasion, and downregulation of EBV micro RNAs.[222,223]

Downloaded from ashpublications.org/blood/article-pdf/140/11/1229/1921035/bloodbld2022015851c.pdf by guest on 15 September 2026

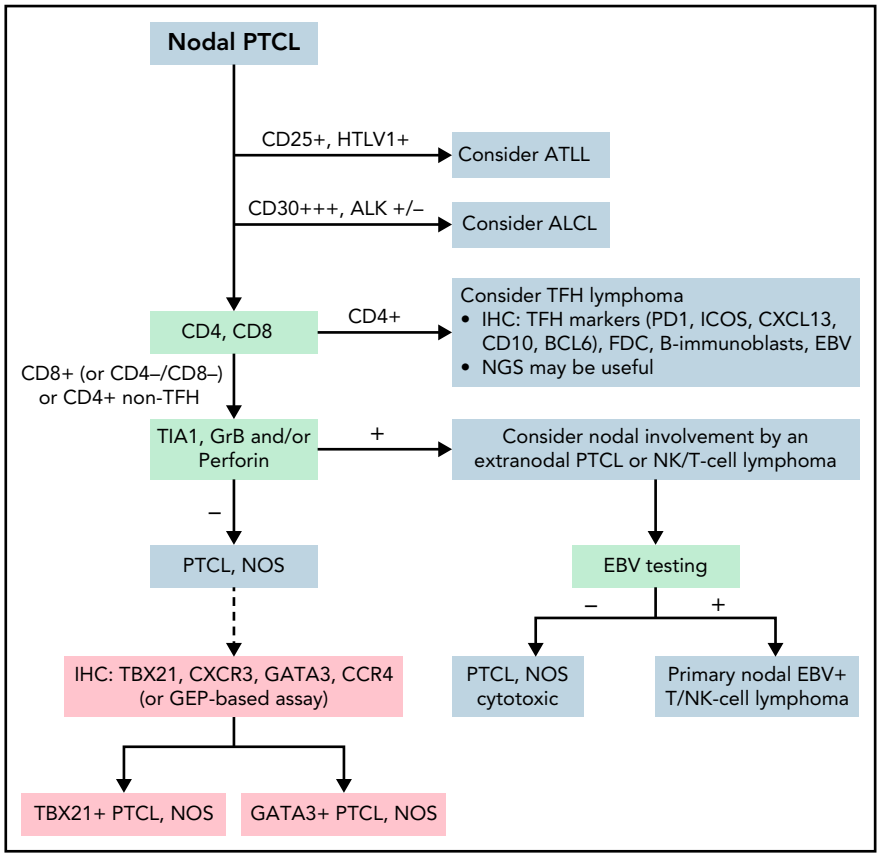


**Figure 5. Algorithm for the classification workup of nodal PTCLs.** The current algorithm for diagnosing PTCL requires immunophenotypic study with a panel of markers that, together with viral analysis (HTLV1, EBV), will orient the pathologist to consider and diagnose specific entities. In ambiguous cases, sequencing studies may help diagnose some entities, particularly follicular helper T-cell lymphoma. PTCL, NOS is established when other specific entities are excluded. Phenotypic analysis or analysis by GEP may subdivide patients with PTCL, NOS, but this subclassification is not routinely incorporated into clinical diagnosis and requires further studies for clinical validation. ATLL, adult T-cell leukemia/lymphoma; GrB, granzyme B; Per, perforine.

## Extranodal T-cell and NK-cell neoplasms involving the gastrointestinal tract

The two main types of primary intestinal T-cell lymphomas are enteropathy-associated T-cell lymphoma (EATL), which may be preceded by refractory celiac disease, and monomorphic epitheliotropic intestinal T-cell lymphoma (MEITL).[7] Novel immunophenotypic and genomic data reinforce their distinction.[224] Expression of SYK is absent in EATL.[225] Most patients with EATL are T-cell receptor (TCR)–silent, whereas most patients with MEITL express the TCR and derive more frequently from gamma-delta T cells than from alpha-beta T cells.[225-229] MEITL has highly recurrent alterations in *SETD2*, resulting in defective trimethylation of H3K36 and frequent mutations in *STAT5B*, *JAK3*, *TP53*, and *GNAI2*.[228-232] Type II refractory celiac disease is a precursor of EATL and has therefore been added to the classification. EATL and type II refractory celiac disease have frequent gain-of-function mutations in *STAT3* and *JAK1*.[229,233-235] Intestinal T-cell lymphoma, NOS remains an entity for overtly malignant primary intestinal EBV-negative T-cell lymphomas, after EATL, MEITL, and other PTCL entities, notably adult T-cell lymphoma/leukemia, have been excluded.

Two groups of indolent LPDs of the gastrointestinal tract are recognized, according to their T-cell or NK-cell derivation.[236-239] The clonal nature of the T-cell disease (indolent clonal T-cell LPD of the gastrointestinal tract), which variably express CD4 and/or CD8, is further supported by the finding of gene alterations in a subset of the patients.[240-242] The intestinal NK-cell proliferation formerly referred to as NK-cell enteropathy[237] or lymphomatoid gastropathy,[243] is now recognized as a neoplasm designated as indolent NK-cell LPD of the gastrointestinal tract.[236] These 2 entities are EBV negative and have a limited propensity to infiltrate the gastrointestinal tract with a superficial distribution.

## Peripheral T-cell lymphoma, NOS

PTCL, NOS is mainly a nodal lymphoma that remains a diagnosis of exclusion (Figure 5). Two molecular subgroups—PTCL-TBX21 and PTCL-GATA3—have been identified based on their GEP resembling T helper type 1 (Th1) and Th2 cells, respectively. The PTCL-GATA3 subgroup has been associated with a worse outcome in some studies and has greater genomic complexity.[244] The PTCL-TBX21 subgroup has better prognosis, fewer copy number alterations, and more frequent mutations in genes that regulate DNA methylation.[244] These subgroups may be recognized by using an immunohistochemistry-based algorithm with 4 markers (TBX21, CXCR3, GATA3, and CCR4).[245-247] In addition, the expression of cytotoxic molecules delineates a subgroup of aggressive PTCLs, NOS which tend to occur in patients with impaired immunity and mostly cluster to PTCL-TBX21.[244,248] Designation of PTCL, NOS according to the

Downloaded from ashpublications.org/blood/article-pdf/140/11/1229/1921035/bloodbld2022015851c.pdf by guest on 15 September 2026

molecular subgroups is not routinely incorporated into clinical diagnosis and requires further studies for clinical validation.

### Follicular helper T-cell lymphoma

Since the discovery that T follicular helper (TFH) cells represent the normal cell counterpart of the neoplastic cells in angioimmunoblastic T-cell lymphoma (AITL),[249,250] a larger subset of nodal PTCLs not diagnostic of AITL have been found to express markers of normal TFH cells and/or are more GEP-enriched than normal TFH cells.[251] The 2016 WHO classification created an umbrella category of "nodal lymphomas of TFH origin," covering 3 entities, namely AITL, follicular helper T-cell lymphoma, and PTCL with TFH phenotype showing a diffuse or T-zone pattern without follicular dendritic cell (FDC) expansion.[5] A TFH phenotype was defined by the expression of 2 or preferably 3 phenotypic markers of normal TFH cells, among which those most widely used are CD10, BCL6, CXCL13, PD1, and ICOS.[251-253] Multiple studies have reinforced the notion that these 3 entities are unified by a common genetic landscape in addition to a TFH immunophenotype.[251,252,254] Loss-of-function mutations in genes that regulate DNA and histone methylation, specifically *TET2* (present in about 80%), and/or *DNMT3A* (present in 30%-40%) of the patients, and several lines of evidence, indicate that AITL in many instances develops on a background of clonal hematopoiesis. Other alterations include a highly recurrent *RHOA*$^{G17V}$ hotspot mutation, mutations in *IDH2*$^{R172}$, and mutations in genes involved in TCR signaling.[251,255] *IDH2* mutations seem to be restricted to AITL with characteristic large clear-cell cytomorphology.[253] Several pathogenic fusions involving *CD28*, *ICOS*, and *VAV1* have been reported.[256] Overall, the combinatory pattern of mutations in genes related to epigenetics and TCR signaling is a feature common to all nodal lymphomas of TFH origin. These lymphomas show a better response to histone deacetylase inhibitors compared with other PTCLs, which suggests the clinical relevance of the TFH phenotype.[257-259] For these reasons, the ICC unifies systemic lymphomas of TFH origin as a single entity—TFH lymphoma—with 3 subtypes: angioimmunoblastic-type (AITL), follicular-type, and NOS. By definition, this entity is restricted to patients with primary nodal or systemic disease and excludes primary cutaneous small or medium CD4$^+$ T-cell LPDs or other specified subtypes of cutaneous lymphomas with a TFH phenotype.[260] The criteria for distinguishing the 3 TFH lymphoma subtypes remain essentially unchanged and rely mainly on morphology and immunoarchitecture, especially the tumor microenvironment and distribution of FDCs. For establishing the TFH immunophenotype, which is critical for the diagnosis of TFH lymphomas of follicular type and NOS, we recommend the use of a 5-marker panel. Because *RHOA*$^{G17V}$ or *IDH2*$^{R172}$ are so characteristic of TFH lymphomas, especially of the AITL type, NGS studies are valuable in supporting a diagnosis of TFH lymphoma.[261]

### Anaplastic large-cell lymphoma

ALK-negative anaplastic large-cell lymphoma (ALCL) remains a distinct systemic entity. Primary cutaneous ALCL and breast implant–associated ALCL must be excluded from this category. Criteria for the diagnosis remain unchanged. The disease should resemble ALK-positive ALCL with a common pattern, have strong uniform CD30 expression, and lack ALK expression. *DUSP22*-R ALK-negative ALCL is now defined as a genetic subtype of systemic ALK-negative ALCL based on distinct morphologic, phenotypic, genomic, and epigenetic features.[192,262-266] *DUSP22*-R is present in 19% to 30% of ALK-negative ALCLs, and FISH testing is recommended in all ALK-negative ALCLs. *DUSP22*-R ALCL tends to have a favorable prognosis, but in some patients, it may behave aggressively, probably related to high International Prognostic Index (IPI) score and other high-risk clinical features.[262,265-267] *TP63* rearrangements are associated with poor prognosis. Patients with the rare co-existing *TP63*-R and *DUSP22*-R require further study.[268] Patients with *JAK2*-R may have a disease that resembles CHL, which presents a potential diagnostic challenge.[269]

Breast implant–associated ALCL was upgraded to a definite entity based on its unique clinical, genomic, and molecular features distinct from other ALCLs.[270-275] Pathologic and clinical staging is important to determine prognosis and assess the need for chemotherapy. Formation of a mass lesion, capsular invasion, and lymph node involvement are adverse prognostic features.[276,277] Comprehensive capsulectomy sampling,[278] margin evaluation, and use of tumor-node-metastasis (TNM) staging criteria (T1: in situ, tumor cells in seroma and/or on capsular luminal surface; T2: early capsule infiltration; T3: aggregates or sheets infiltrating capsule; T4: infiltration beyond capsule) are recommended.[277]

## Cutaneous lymphomas

Several significant changes are being introduced in the ICC regarding primary cutaneous lymphomas. Primary cutaneous marginal zone lymphoproliferations will now be recognized as distinct from other MALT lymphomas. They will now be called "primary cutaneous marginal zone LPD" rather than "lymphoma" because of their extremely indolent behavior; disease-specific survivals approach 100% without requiring aggressive therapies. However, cutaneous recurrences are common. Primary cutaneous marginal zone LPDs show significant differences compared with MALT lymphomas at other sites.[7,279-285] Two subtypes of this disorder are recognized, largely but not exclusively identified on the basis of whether they are heavy chain, class-switched, or IgM positive.[7,283,285-287] Approximately three-quarters of primary cutaneous marginal zone LPDs are class-switched and predominantly IgG$^+$ with up to ~40% expressing IgG4.[285,288] These patients often have other unique features, including abundant reactive T cells and peripherally located plasma cells. Caution must be taken with IgM$^+$ tumors to exclude non-cutaneous primary disease.[280,283,287] Rare patients with class-switched disease are similar to those with IgM$^+$ primary cutaneous marginal zone LPDs and have features more like those in patients with typical MALT lymphomas.[287] Molecular and genetic studies of both primary cutaneous marginal zone and primary cutaneous follicle center lymphomas have further supported their recognition as distinct entities and have potential diagnostic utility.[289-291]

Primary cutaneous DLBCL, leg type remains a distinct entity. Many patients share the molecular and cytogenetic features seen in DLBCL of MCD/C5 type, a finding also shared with PCNSL, primary DLBCL of the testis, and intravascular large B-cell lymphoma.[133,135,138,292,293] About 25% of the latter are restricted to the skin and reported to have a better prognosis than the systemic variant.[138,294,295] Primary cutaneous DLBCL, leg type, is considered to be of the non-GCB/ABC type, but one study reported that these patients may be more

Downloaded from ashpublications.org/blood/article-pdf/140/11/1229/1921035/bloodbld2022015851c.pdf by guest on 15 September 2026

heterogeneous in terms of their cell-of-origin with frequent *MYD88* and *CD79B* mutations.[296] However, this study includes a large number of unclassified patients by GEP and triple-positive patients by Hans algorithm (CD10, BCL6, and IRF4/MUM1). Consistent with the recognition that some high-grade B-cell lymphomas can be TdT positive, some patients have been reported with TdT positivity, which should not prompt reclassification of their disease as a B-cell lymphoblastic neoplasm.[297,298]

There are new molecular and cytogenetic data regarding a variety of cutaneous T-cell lymphomas of biologic and, to some extent, clinical and potential therapeutic interest. This includes specific findings such as the germline *HAVCR2* mutations in many patients with subcutaneous panniculitis-like T-cell lymphomas[299-301] and also the more extensive genetic and epigenetic findings in other cutaneous T-cell lymphomas, including mycosis fungoides and Sézary syndrome.[302] However, there is only one significant change in the classification of the primary cutaneous T-cell lymphomas. Consistent with a general trend to greater conservatism, primary cutaneous acral $CD8^+$ T-cell lymphoma, in spite of its very monotonous and atypical morphologic appearance, is now classified as a primary cutaneous acral $CD8^+$ T-cell LPD, largely because of its very indolent course and general need for only local type therapies or even just observation.[303-305] Although ~20% of patients do have a local or more extensive recurrence, only 1 patient with extracutaneous spread is described, and a 100% survival rate is reported independent of treatment modality.[281,305] Some do still advise clinical caution.[306] Aiding in their distinction from other $CD8^+$ cutaneous T-cell lymphomas is their characteristic dot-like CD68 positivity in the neoplastic cells.[307] A rare $CD4^+CD8^+$ patient has been reported.[308]

## Immunodeficiency-associated lymphoproliferative disorders

The iatrogenic immunodeficiency-associated LPDs include post-transplant LPD (PTLD), and the separately designated LPD arising in patients receiving methotrexate or other immunosuppressive agents.[7] Although there are some common histologic features shared by EBV-positive B-cell LPDs in diverse clinical settings,[150] the consensus was to retain PTLD as a separate subgroup based in part on major differences in clinical management. Subclassification of PTLDs, not all of which are EBV-positive, remains unaltered from the 2017 WHO classification.[7] Although studies of other iatrogenic immunodeficiency-associated LPDs are much more limited, it is recommended that they be classified in a fashion analogous to PTLD. This was a topic not discussed in great detail at the CAC and requires further study.

## Histiocytic and dendritic cell neoplasms

The classification of histiocytic and dendritic cell neoplasms has matured in recent years.[309] Delineation of B-cell and T-cell lymphomas developed from a concerted effort to relate the tumors to developmental and functional subsets of the normal immune system,[310] while many of the histiocytoses were initially thought to be reactive or inflammatory conditions. The list includes Erdheim-Chester disease, Rosai-Dorfman-Destombes disease, and Langerhans cell histiocytosis.

Study of the molecular pathogenesis of these neoplasms indicates convergence along a common pathway, with frequent mutations in the mitogen-activated protein kinase (MAPK) pathway.[311,312] A smaller subset of patients shows evidence of activation of the PI3K signaling pathway.[313] These insights have led to advances in therapy, with the introduction of targeted therapy through inhibition of *RAS*, *RAF*, *MEK*, and *MTOR*.[309,313] Nevertheless, many of the observed mutations are not specific to any individual entity. For example, $BRAF^{V600E}$ mutations can be encountered in all members of the disease family, including isolated Langerhans cell histiocytosis, systemic Erdheim-Chester disease, and histiocytic and dendritic cell sarcomas. ALK-positive histiocytosis is a relatively new addition to the list of histiocytic neoplasms,[314,315] and involves rearrangements of *ALK*, leading to activation of signaling pathways. First described by Chan et al,[316] the cells have a mature histiocytic phenotype and often have foamy cytoplasm. Patients who present in infancy usually have systemic disease, whereas patients who present as adults usually have more localized disease.

EBV-positive inflammatory FDC/fibroblastic reticular cell (FRC) tumor is an indolent proliferation of stromal cells of mesenchymal origin not derived from hematopoietic stem cells. Neoplastic cells are EBV positive and are associated with a rich inflammatory background. Spleen and liver are the most common sites, but the tumors also arise in other extranodal locations.[317-319]

## Conclusion

The clinicopathological, molecular, and genomic information generated on lymphoid neoplasms in the last 5 years provides solid grounds for refining the diagnostic criteria of several entities, consolidating the status of categories previously defined as provisional, and identifying some new entities. The explosion of genomic data is having an impact on our understanding of these diseases and is starting to be introduced into routine clinical practice for diagnosis and management strategies. However, in many areas, incorporation of these data into general practice requires further validation and standardization.

## Acknowledgments

We dedicate this report to the memory of Paul Kleihues (21 May 1936–17 March 2022), former director of the International Agency for Research on Cancer (IARC) (1994-2003), a visionary leader who created the modern WHO Blue Book series for the classification of tumors.

E.S.J., L.M.S., and J.I.C. were supported by the intramural research programs of the Center for Cancer Research, National Cancer Institute (E.S.J., ZIA SC 000550; L.M.S., ZIABC011780) and the National Institute of Allergy and Infectious Diseases (J.I.C., ZIAAI000058). Funding for the work of the CAC was received from many sources as previously cited.[5]

## Authorship

Contribution: E.C., E.S.J., J.R.C., L.Q.-M., S.H.S., K.C.A., P.B., L.C., L.d.L., S.D., A. Dogan, A.L.F., F.F., J.W.F., P. Gaulard, P. Ghia, S.M.H., R.L.K.,

Downloaded from ashpublications.org/blood/article-pdf/140/11/1229/1921035/bloodbld2022015851c.pdf by guest on 15 September 2026

G.S., J.S.-M., J.F.S., S.P.T., J.M.V., E.Z., R.A., S.A., W.-Y.A., C.B., L.B., W.C.C., J.I.C., F.d'A., A. Davies, B.F., I.M.G., J.G., J.G.G., E.D.H., B.S.K., W.-S.K., S.K., A.S.L., C.L., G.L., J.P.L., M.P.L., A.L.-G., M.V.M., E.M., A.M.M., F.M., S.N., M.N., A.P., S.A.P., M.P., B.P., V.R., S.T.R., B.S., L.S., M.A.S., S.M.S., L.M.S., C.T., T.T., W.H.W., T.Y., P.-L.Z., M.D., D.W.S., J.N.W., and A.D.Z. contributed to the contents of this manuscript; and E.C., E.S.J., J.R.C., M.D., L.Q.-M., D.W.S., S.H.S., J.N.W., and A.D.Z. coordinated the work of the Clinical Advisory Committee and edited the final manuscript.

Conflict-of-interest disclosure: The authors declare no competing financial interests.

ORCID profiles: E.C., 0000-0001-9850-9793; E.S.J., 0000-0003-4632-0301; J.R.C., 0000-0003-0456-8085; L.Q.-M., 0000-0001-7156-5365; P.B., 0000-0002-8629-3291; A.D., 0000-0001-6576-5256; A.L.F., 0000-0001-5009-4808; P.G., 0000-0003-3750-7342; G.S., 0000-0002-9541-8666; J.S.-M., 0000-0002-9183-4857; J.F.S., 0000-0003-2188-6835; S.P.T., 0000-0001-6393-6154; J.M.V., 0000-0003-1015-7434; E.Z., 0000-0002-5522-6109; C.B., 0000-0003-2474-914X; L.B., 0000-0003-1523-7388; A.D., 0000-0002-7517-6938; B.F., 0000-0002-7198-5965; I.M.G., 0000-0001-7361-3092; J.R.G., 0000-0002-8385-8517; J.G.G., 0000-0002-8505-7430; E.D.H., 0000-0001-8623-4067; B.S.K., 0000-0003-0459-6609; S.K., 0000-0001-5392-9284; A.S.L., 0000-0001-7349-0176; M.-V.M.M., 0000-0003-2390-1218; E.M., 0000-0003-0520-0493; A.M.M., 0000-0002-8074-2287; F.M., 0000-0002-3714-9824; S.A.P., 0000-0001-8032-5128; M.P., 0000-0001-5839-3634; M.A.S., 0000-0002-3949-6897; S.M.S., 0000-0002-9893-4949; P.-L.Z., 0000-0002-2112-2651; M.D., 0000-0002-0358-5249; D.W.S., 0000-0002-0435-5947; A.D.Z., 0000-0003-1403-6883.

Correspondence: Elias Campo, Hematopathology Unit, Laboratory of Pathology, Hospital Clinic of Barcelona, Villarroel 170, 08036 Barcelona, Spain; e-mail: ecampo@clinic.cat; and Elaine S. Jaffe, Hematopathology Unit, Laboratory of Pathology, 10 Center Dr, Room 3S 235, National Cancer Institute, National Institutes of Health, Bethesda, MD 20892; e-mail: ejaffe@mail.nih.gov.

## Footnotes

Submitted 14 April 2022; accepted 18 May 2022; prepublished online on *Blood* First Edition 2 June 2022. DOI 10.1182/blood.2022015851.

The online version of this article contains a data supplement.

Downloaded from ashpublications.org/blood/article-pdf/140/11/1229/1921035/bloodbld2022015851c.pdf by guest on 15 September 2026

## REFERENCES

1. Harris NL, Jaffe ES, Stein H, et al. A revised European-American Classification of Lymphoid Neoplasms: a proposal from the International Lymphoma Study Group. *Blood*. 1994;84(5):1361-1392.

2. A clinical evaluation of the International Lymphoma Study Group classification of non-Hodgkin's lymphoma. The Non-Hodgkin's Lymphoma Classification Project. *Blood*. 1997;89(11):3909-3918.

3. Jaffe ES, Harris NL, Stein H, Vardiman J, eds. Pathology and Genetics of Tumours of Haematopoietic and Lymphoid Tissues. Lyon, France: International Agency for Research on Cancer Press; 2001.

4. Campo E, Swerdlow SH, Harris NL, Pileri S, Stein H, Jaffe ES. The 2008 WHO classification of lymphoid neoplasms and beyond: evolving concepts and practical applications. *Blood*. 2011;117(19): 5019-5032.

5. Swerdlow SH, Campo E, Pileri SA, et al. The 2016 revision of the World Health Organization Classification of Lymphoid Neoplasms. *Blood*. 2016;127(20): 2375-2390.

6. Swerdlow SH, Campo E, Harris NL, et al, eds. WHO Classification of Tumours of Haematopoietic and Lymphoid Tissues.4th ed. Lyon, France: International Agency for Research on Cancer; 2008.

7. Swerdlow SH, Campo E, Harris NL, Jaffe ES, Pileri SA, Thiele J , eds. WHO Classification of Tumours of Haematopoietic and Lymphoid Tissues. Revised 4th ed. Lyon, France: International Agency for Research on Cancer; 2017.

8. Hallek M, Cheson BD, Catovsky D, et al. iwCLL guidelines for diagnosis, indications for treatment, response assessment, and supportive management of CLL. *Blood*. 2018;131(25):2745-2760.

9. Puente XS, Beà S, Valdés-Mas R, et al. Non-coding recurrent mutations in chronic lymphocytic leukaemia. *Nature*. 2015; 526(7574):519-524.

10. Landau DA, Tausch E, Taylor-Weiner AN, et al. Mutations driving CLL and their evolution in progression and relapse. *Nature*. 2015;526(7574):525-530.

11. Beekman R, Chapaprieta V, Russiñol N, et al. The reference epigenome and regulatory chromatin landscape of chronic lymphocytic leukemia. *Nat Med*. 2018; 24(6):868-880.

12. Rossi D, Khiabanian H, Spina V, et al. Clinical impact of small TP53 mutated subclones in chronic lymphocytic leukemia. *Blood*. 2014;123(14):2139-2147.

13. Nadeu F, Delgado J, Royo C, et al. Clinical impact of clonal and subclonal TP53, SF3B1, BIRC3, NOTCH1, and ATM mutations in chronic lymphocytic leukemia. *Blood*. 2016;127(17):2122-2130.

14. Bomben R, Rossi FM, Vit F, et al. *TP53* mutations with low variant allele frequency predict short survival in chronic lymphocytic leukemia. *Clin Cancer Res*. 2021;27(20): 5566-5575.

15. Stamatopoulos K, Agathangelidis A, Rosenquist R, Ghia P. Antigen receptor stereotypy in chronic lymphocytic leukemia. *Leukemia*. 2017;31(2):282-291.

16. Maity PC, Bilal M, Koning MT, et al. *IGLV3-21*01* is an inherited risk factor for CLL through the acquisition of a single-point mutation enabling autonomous BCR signaling. *Proc Natl Acad Sci USA*. 2020;117(8): 4320-4327.

17. Nadeu F, Royo R, Clot G, et al. IGLV3-21R110 identifies an aggressive biological subtype of chronic lymphocytic leukemia with intermediate epigenetics. *Blood*. 2021;137(21):2935-2946.

18. Baliakas P, Jeromin S, Iskas M, et al; ERIC, the European Research Initiative on CLL. Cytogenetic complexity in chronic lymphocytic leukemia: definitions, associations, and clinical impact. *Blood*. 2019;133(11):1205-1216.

19. Gibson SE, Swerdlow SH, Ferry JA, et al. Reassessment of small lymphocytic lymphoma in the era of monoclonal B-cell lymphocytosis. *Haematologica*. 2011;96(8): 1144-1152.

20. Habermehl GK, Durkin L, Hsi ED. A tissue counterpart to monoclonal B-cell lymphocytosis. *Arch Pathol Lab Med*. 2021; 145(12):1544-1551.

21. Giné E, Martinez A, Villamor N, et al. Expanded and highly active proliferation centers identify a histological subtype of chronic lymphocytic leukemia ("accelerated" chronic lymphocytic leukemia) with aggressive clinical behavior. *Haematologica*. 2010;95(9):1526-1533.

22. Barnea Slonim L, Ma S, Behdad A, Chen Q. Pseudo-Richter transformation of chronic lymphocytic leukaemia/small lymphocytic lymphoma following ibrutinib interruption: a diagnostic pitfall. *Br J Haematol*. 2020; 191(1):e22-e25.

23. Hampel PJ, Cherng HJ, Call TG, et al. Incidental Richter transformation in chronic lymphocytic leukemia patients during temporary interruption of ibrutinib. *Blood Adv*. 2020;4(18):4508-4511.

24. Piva R, Deaglio S, Famà R, et al. The Krüppel-like factor 2 transcription factor gene is recurrently mutated in splenic marginal zone lymphoma. *Leukemia*. 2015; 29(2):503-507.

25. Clipson A, Wang M, de Leval L, et al. KLF2 mutation is the most frequent somatic change in splenic marginal zone lymphoma and identifies a subset with distinct genotype. *Leukemia*. 2015;29(5): 1177-1185.

26. Campos-Martín Y, Martínez N, Martínez-López A, et al. Clinical and diagnostic relevance of *NOTCH2*-and *KLF2*-mutations in splenic marginal zone lymphoma. *Haematologica*. 2017;102(8):e310-e312.

27. Bonfiglio F, Bruscaggin A, Guidetti F, et al. Genetic and phenotypic attributes of splenic marginal zone lymphoma. *Blood*. 2022;139(5):732-747.

28. Owen RG, Treon SP, Al-Katib A, et al. Clinicopathological definition of Waldenstrom's macroglobulinemia: consensus panel recommendations from the Second International Workshop on Waldenstrom's Macroglobulinemia. *Semin Oncol*. 2003;30(2):110-115.

29. Treon SP, Xu L, Yang G, et al. MYD88 L265P somatic mutation in Waldenström's macroglobulinemia. *N Engl J Med*. 2012; 367(9):826-833.

30. Mori N, Ohwashi M, Yoshinaga K, et al. L265P mutation of the MYD88 gene is frequent in Waldenström's macroglobulinemia and its absence in myeloma. *PLoS One*. 2013;8(11):e80088.

31. Jiménez C, Sebastián E, Chillón MC, et al. MYD88 L265P is a marker highly characteristic of, but not restricted to, Waldenström's macroglobulinemia. *Leukemia*. 2013;27(8):1722-1728.

32. Treon SP, Gustine J, Xu L, et al. MYD88 wild-type Waldenstrom Macroglobulinaemia: differential diagnosis, risk of histological transformation, and overall survival. *Br J Haematol*. 2018;180(3):374-380.

33. Hunter ZR, Xu L, Tsakmaklis N, et al. Insights into the genomic landscape of MYD88 wild-type Waldenström macroglobulinemia. *Blood Adv*. 2018;2(21): 2937-2946.

34. Xu L, Hunter ZR, Tsakmaklis N, et al. Clonal architecture of CXCR4 WHIM-like mutations in Waldenström Macroglobulinaemia. *Br J Haematol*. 2016;172(5):735-744.

35. Hunter ZR, Xu L, Yang G, et al. The genomic landscape of Waldenstrom macroglobulinemia is characterized by highly recurring MYD88 and WHIM-like CXCR4 mutations, and small somatic deletions associated with B-cell lymphomagenesis. *Blood*. 2014;123(11):1637-1646.

36. Kaiser LM, Hunter ZR, Treon SP, Buske C. CXCR4 in Waldenström's Macroglobulinema: chances and challenges. *Leukemia*. 2021;35(2):333-345.

37. Rajkumar SV, Dimopoulos MA, Palumbo A, et al. International Myeloma Working Group updated criteria for the diagnosis of multiple myeloma. *Lancet Oncol*. 2014; 15(12):e538-e548.

38. Randen U, Trøen G, Tierens A, et al. Primary cold agglutinin-associated lymphoproliferative disease: a B-cell lymphoma of the bone marrow distinct from lymphoplasmacytic lymphoma. *Haematologica*. 2014; 99(3):497-504.

39. Małecka A, Trøen G, Tierens A, et al. Frequent somatic mutations of KMT2D (MLL2) and CARD11 genes in primary cold agglutinin disease. *Br J Haematol*. 2018; 183(5):838-842.

40. Małecka A, Delabie J, Østlie I, et al. Cold agglutinin-associated B-cell lymphoproliferative disease shows highly recurrent gains of chromosome 3 and 12 or 18. *Blood Adv*. 2020;4(6):993-996.

41. Bergsagel PL, Kuehl WM. Molecular pathogenesis and a consequent classification of multiple myeloma. *J Clin Oncol*. 2005;23(26):6333-6338.

42. Fonseca R, Bergsagel PL, Drach J, et al; International Myeloma Working Group. International Myeloma Working Group molecular classification of multiple myeloma: spotlight review. *Leukemia*. 2009;23(12):2210-2221.

43. Schinke C, Hoering A, Wang H, et al. The prognostic value of the depth of response in multiple myeloma depends on the time of assessment, risk status and molecular subtype. *Haematologica*. 2017;102(8): e313-e316.

44. Zhan F, Huang Y, Colla S, et al. The molecular classification of multiple myeloma. *Blood*. 2006;108(6):2020-2028.

45. Walker BA, Mavrommatis K, Wardell CP, et al. Identification of novel mutational drivers reveals oncogene dependencies in multiple myeloma. *Blood*. 2018;132(6): 587-597.

46. Palumbo A, Avet-Loiseau H, Oliva S, et al. Revised International Staging System for Multiple Myeloma: a report from International Myeloma Working Group. *J Clin Oncol*. 2015;33(26):2863-2869.

47. Sonneveld P, Avet-Loiseau H, Lonial S, et al. Treatment of multiple myeloma with high-risk cytogenetics: a consensus of the International Myeloma Working Group. *Blood*. 2016;127(24):2955-2962.

48. Pawlyn C, Morgan GJ. Evolutionary biology of high-risk multiple myeloma. *Nat Rev Cancer*. 2017;17(9):543-556.

49. Rasche L, Chavan SS, Stephens OW, et al. Spatial genomic heterogeneity in multiple myeloma revealed by multi-region sequencing. *Nat Commun*. 2017;8(1):268.

50. Ledergor G, Weiner A, Zada M, et al. Single cell dissection of plasma cell heterogeneity in symptomatic and asymptomatic myeloma. *Nat Med*. 2018; 24(12):1867-1876.

51. Manier S, Salem KZ, Park J, Landau DA, Getz G, Ghobrial IM. Genomic complexity of multiple myeloma and its clinical implications. *Nat Rev Clin Oncol*. 2017; 14(2):100-113.

52. Weiss BM, Abadie J, Verma P, Howard RS, Kuehl WM. A monoclonal gammopathy precedes multiple myeloma in most patients. *Blood*. 2009;113(22):5418-5422.

53. Leung N, Bridoux F, Nasr SH. Monoclonal gammopathy of renal significance. *N Engl J Med*. 2021;384(20):1931-1941.

54. Fermand JP, Bridoux F, Dispenzieri A, et al. Monoclonal gammopathy of clinical significance: a novel concept with therapeutic implications. *Blood*. 2018; 132(14):1478-1485.

55. Mateos MV, Kumar S, Dimopoulos MA, et al. International Myeloma Working Group risk stratification model for smoldering multiple myeloma (SMM). *Blood Cancer J*. 2020;10(10):102.

56. Caers J, Paiva B, Zamagni E, et al. Diagnosis, treatment, and response assessment in solitary plasmacytoma: updated recommendations from a European Expert Panel. *J Hematol Oncol*. 2018;11(1):10.

57. Nahi H, Genell A, Wålinder G, et al. Incidence, characteristics, and outcome of solitary plasmacytoma and plasma cell leukemia. Population-based data from the Swedish Myeloma Register. *Eur J Haematol*. 2017;99(3):216-222.

58. Paiva B, Chandia M, Vidriales MB, et al. Multiparameter flow cytometry for staging of solitary bone plasmacytoma: new criteria for risk of progression to myeloma. *Blood*. 2014;124(8):1300-1303.

59. Mahmood S, Bridoux F, Venner CP, et al. Natural history and outcomes in localised immunoglobulin light-chain amyloidosis: a long-term observational study. *Lancet Haematol*. 2015;2(6):e241-e250.

60. Kourelis TV, Kyle RA, Dingli D, et al. Presentation and outcomes of localized immunoglobulin light chain amyloidosis: the Mayo Clinic experience. *Mayo Clin Proc*. 2017;92(6):908-917.

61. Basset M, Hummedah K, Kimmich C, et al. Localized immunoglobulin light chain amyloidosis: novel insights including prognostic factors for local progression. *Am J Hematol*. 2020;95(10):1158-1169.

62. Koch K, Hoster E, Ziepert M, et al. Clinical, pathological and genetic features of follicular lymphoma grade 3A: a joint analysis of the German low-grade and high-grade lymphoma study groups GLSG and DSHNHL. *Ann Oncol*. 2016;27(7): 1323-1329.

63. Mustafa Ali M, Rybicki L, Nomani L, et al. Grade 3 follicular lymphoma: outcomes in the rituximab era. *Clin Lymphoma Myeloma Leuk*. 2017;17(12):797-803.

64. Shah NN, Szabo A, Saba R, et al. Multicenter analysis of advanced stage grade 3A follicular lymphoma outcomes by frontline treatment regimen. *Clin Lymphoma Myeloma Leuk*. 2019;19(2): 95-102.

65. Barraclough A, Bishton M, Cheah CY, Villa D, Hawkes EA. The diagnostic and therapeutic challenges of grade 3B follicular lymphoma. *Br J Haematol*. 2021; 195(1):15-24.

66. Koch K, Richter J, Hanel C, Huttmann A, Duhrsen U, Klapper W. Follicular lymphoma grade 3B and diffuse large B-cell lymphoma present a histopathological and molecular continuum lacking features of progression/transformation [published online ahead of print 13 January 2022]. *Haematologica*. doi:10.3324/haematol.2021.279351.

67. Laurent C, Adélaïde J, Guille A, et al; Lymphoma Study Association (LYSA). High-grade follicular lymphomas exhibit clinicopathologic, cytogenetic, and molecular diversity extending beyond grades 3A and 3B. *Am J Surg Pathol*. 2021; 45(10):1324-1336.

Downloaded from ashpublications.org/blood/article-pdf/140/11/1229/1921035/bloodbld2022015851c.pdf by guest on 15 September 2026

68. Quintanilla-Martinez L, Sander B, Chan JK, et al. Indolent lymphomas in the pediatric population: follicular lymphoma, IRF4/MUM1+ lymphoma, nodal marginal zone lymphoma and chronic lymphocytic leukemia. *Virchows Arch*. 2016;468(2):141-157.

69. Ramis-Zaldivar JE, Gonzalez-Farré B, Balagué O, et al. Distinct molecular profile of IRF4-rearranged large B-cell lymphoma. *Blood*. 2020;135(4):274-286.

70. Miyaoka M, Kikuti YY, Carreras J, et al. Clinicopathological and genomic analysis of double-hit follicular lymphoma: comparison with high-grade B-cell lymphoma with MYC and BCL2 and/or BCL6 rearrangements. *Mod Pathol*. 2018;31(2):313-326.

71. Ziemba JB, Wolf Z, Weinstock M, Asakrah S. Double-hit and triple-hit follicular lymphoma. *Am J Clin Pathol*. 2020;153(5):672-685.

72. Chaudhary S, Brown N, Song JY, et al. Relative frequency and clinicopathologic characteristics of MYC-rearranged follicular lymphoma. *Hum Pathol*. 2021;114:19-27.

73. Bussot L, Chevalier S, Cristante J, et al. Adverse outcome in follicular lymphoma is associated with MYC rearrangements but not MYC extra copies. *Br J Haematol*. 2021;194(2):382-392.

74. Sohani AR, Maurer MJ, Giri S, et al. Biomarkers for risk stratification in patients with previously untreated follicular lymphoma receiving anti-CD20-based biological therapy. *Am J Surg Pathol*. 2021;45(3):384-393.

75. Morschhauser F, Tilly H, Chaidos A, et al. Tazemetostat for patients with relapsed or refractory follicular lymphoma: an open-label, single-arm, multicentre, phase 2 trial. *Lancet Oncol*. 2020;21(11):1433-1442.

76. Pastore A, Jurinovic V, Kridel R, et al. Integration of gene mutations in risk prognostication for patients receiving first-line immunochemotherapy for follicular lymphoma: a retrospective analysis of a prospective clinical trial and validation in a population-based registry. *Lancet Oncol*. 2015;16(9):1111-1122.

77. Siddiqi IN, Friedman J, Barry-Holson KQ, et al. Characterization of a variant of t(14;18) negative nodal diffuse follicular lymphoma with CD23 expression, 1p36/TNFRSF14 abnormalities, and STAT6 mutations. *Mod Pathol*. 2016;29(6):570-581.

78. Xian RR, Xie Y, Haley LM, et al. CREBBP and STAT6 co-mutation and 16p13 and 1p36 loss define the t(14;18)-negative diffuse variant of follicular lymphoma. *Blood Cancer J*. 2020;10(6):69.

79. Nann D, Ramis-Zaldivar JE, Müller I, et al. Follicular lymphoma t(14;18)-negative is genetically a heterogeneous disease. *Blood Adv*. 2020;4(22):5652-5665.

80. Louissaint A Jr, Schafernak KT, Geyer JT, et al. Pediatric-type nodal follicular lymphoma: a biologically distinct lymphoma with frequent MAPK pathway mutations. *Blood*. 2016;128(8):1093-1100.

81. Schmidt J, Gong S, Marafioti T, et al. Genome-wide analysis of pediatric-type follicular lymphoma reveals low genetic complexity and recurrent alterations of TNFRSF14 gene. *Blood*. 2016;128(8):1101-1111.

82. Schmidt J, Ramis-Zaldivar JE, Nadeu F, et al. Mutations of *MAP2K1* are frequent in pediatric-type follicular lymphoma and result in ERK pathway activation. *Blood*. 2017;130(3):323-327.

83. Liu Q, Salaverria I, Pittaluga S, et al. Follicular lymphomas in children and young adults: a comparison of the pediatric variant with usual follicular lymphoma. *Am J Surg Pathol*. 2013;37(3):333-343.

84. Salmeron-Villalobos J, Egan C, Borgmann V, et al. PNMZL and PTFL: morphological variants with a common molecular profile – a unifying hypothesis [published online ahead of print 24 May 2022]. *Blood Adv*. 2022. doi:10.1182/bloodadvances.2022007322.

85. Lones MA, Raphael M, McCarthy K, et al. Primary follicular lymphoma of the testis in children and adolescents. *J Pediatr Hematol Oncol*. 2012;34(1):68-71.

86. Finn LS, Viswanatha DS, Belasco JB, et al. Primary follicular lymphoma of the testis in childhood. *Cancer*. 1999;85(7):1626-1635.

87. Fu K, Weisenburger DD, Greiner TC, et al; Lymphoma/Leukemia Molecular Profiling Project. Cyclin D1-negative mantle cell lymphoma: a clinicopathologic study based on gene expression profiling. *Blood*. 2005;106(13):4315-4321.

88. Wlodarska I, Dierickx D, Vanhentenrijk V, et al. Translocations targeting CCND2, CCND3, and MYCN do occur in t(11;14)-negative mantle cell lymphomas. *Blood*. 2008;111(12):5683-5690.

89. Salaverria I, Royo C, Carvajal-Cuenca A, et al. CCND2 rearrangements are the most frequent genetic events in cyclin D1(-) mantle cell lymphoma. *Blood*. 2013;121(8):1394-1402.

90. Martín-Garcia D, Navarro A, Valdés-Mas R, et al. *CCND2* and *CCND3* hijack immunoglobulin light-chain enhancers in cyclin D1$^-$ mantle cell lymphoma. *Blood*. 2019;133(9):940-951.

91. Sander B, Quintanilla-Martinez L, Ott G, et al. Mantle cell lymphoma – a spectrum from indolent to aggressive disease. *Virchows Arch*. 2016;468(3):245-257.

92. Nishida Y, Takeuchi K, Tsuda K, et al. Acquisition of t(11;14) in a patient with chronic lymphocytic leukemia carrying both t(14;19)(q32;q13.1) and +12. *Eur J Haematol*. 2013;91(2):179-182.

93. Schliemann I, Oschlies I, Nagel I, Maria Murga Penas E, Siebert R, Sander B. The t(11;14)(q13;q32)/CCND1-IGH translocation is a recurrent secondary genetic aberration in relapsed chronic lymphocytic leukemia. *Leuk Lymphoma*. 2016;57(11):2672-2676.

94. Al-Kawaaz M, Mathew S, Liu Y, et al. Cyclin D1-positive diffuse large B-cell lymphoma with IGH-CCND1 translocation and BCL6 rearrangement: a report of two cases. *Am J Clin Pathol*. 2015;143(2):288-299.

95. Parrott AM, Haggiagi AM, Murty VV, Bhagat G, Alobeid B. Primary large B-cell lymphoma of the central nervous system with cyclin D1 expression and t(11;14)(IGH-CCND1): diffuse large B-cell lymphoma with CCND1 rearrangement or mantle cell lymphoma? *Hematol Oncol*. 2020;38(5):817-822.

96. Cheng J, Hashem MA, Barabé F, et al. *CCND1* genomic rearrangement as a secondary event in high grade B-cell lymphoma. *HemaSphere*. 2020;5(1):e505.

97. Koduru PR, Chen W, Garcia R, Fuda F. Acquisition of a t(11;14)(q13;q32) in clonal evolution in a follicular lymphoma with a t(14;18)(q32;q21) and t(3;22)(q27;q11.2). *Cancer Genet*. 2015;208(6):303-309.

98. Wang L, Tang G, Medeiros LJ, et al. *MYC* rearrangement but not extra *MYC* copies is an independent prognostic factor in patients with mantle cell lymphoma. *Haematologica*. 2021;106(5):1381-1389.

99. Nadeu F, Martin-Garcia D, Clot G, et al. Genomic and epigenomic insights into the origin, pathogenesis, and clinical behavior of mantle cell lymphoma subtypes. *Blood*. 2020;136(12):1419-1432.

100. Aukema SM, Croci GA, Bens S, et al. Mantle cell lymphomas with concomitant MYC and CCND1 breakpoints are recurrently TdT positive and frequently show high-grade pathological and genetic features. *Virchows Arch*. 2021;479(1):133-145.

101. Hu Z, Medeiros LJ, Chen Z, et al. Mantle cell lymphoma with MYC rearrangement: a report of 17 patients. *Am J Surg Pathol*. 2017;41(2):216-224.

102. Aukema SM, Hoster E, Rosenwald A, et al. Expression of TP53 is associated with the outcome of MCL independent of MIPI and Ki-67 in trials of the European MCL Network. *Blood*. 2018;131(4):417-420.

103. Eskelund CW, Dahl C, Hansen JW, et al. *TP53* mutations identify younger mantle cell lymphoma patients who do not benefit from intensive chemoimmunotherapy. *Blood*. 2017;130(17):1903-1910.

104. Abrisqueta P, Scott DW, Slack GW, et al. Observation as the initial management strategy in patients with mantle cell lymphoma. *Ann Oncol*. 2017;28(10):2489-2495.

105. Klapper W, Hoster E, Determann O, et al; European MCL Network. Ki-67 as a prognostic marker in mantle cell lymphoma-consensus guidelines of the pathology panel of the European MCL Network. *J Hematop*. 2009;2(2):103-111.

106. Hoster E, Rosenwald A, Berger F, et al. Prognostic value of Ki-67 Index, cytology, and growth pattern in mantle-cell lymphoma: results from randomized trials of the European Mantle Cell Lymphoma Network. *J Clin Oncol*. 2016;34(12):1386-1394.

107. Halldórsdóttir AM, Sander B, Göransson H, et al. High-resolution genomic screening in mantle cell lymphoma – specific changes

Downloaded from ashpublications.org/blood/article-pdf/140/11/1229/1921035/bloodbld2022015851c.pdf by guest on 15 September 2026

correlate with genomic complexity, the proliferation signature and survival. *Genes Chromosomes Cancer*. 2011;50(2):113-121.

108. Clot G, Jares P, Giné E, et al. A gene signature that distinguishes conventional and leukemic nonnodal mantle cell lymphoma helps predict outcome. *Blood*. 2018;132(4):413-422.

109. Orchard J, Garand R, Davis Z, et al. A subset of t(11;14) lymphoma with mantle cell features displays mutated IgVH genes and includes patients with good prognosis, nonnodal disease. *Blood*. 2003;101(12): 4975-4981.

110. Navarro A, Clot G, Royo C, et al. Molecular subsets of mantle cell lymphoma defined by the IGHV mutational status and SOX11 expression have distinct biologic and clinical features. *Cancer Res*. 2012;72(20): 5307-5316.

111. Xu J, Wang L, Li J, et al. SOX11-negative mantle cell lymphoma: clinicopathologic and prognostic features of 75 patients. *Am J Surg Pathol*. 2019;43(5):710-716.

112. Croci GA, Hoster E, Beà S, et al. Reproducibility of histologic prognostic parameters for mantle cell lymphoma: cytology, Ki67, p53 and SOX11. *Virchows Arch*. 2020;477(2):259-267.

113. Morello L, Rattotti S, Giordano L, et al. Mantle cell lymphoma of mucosa-associated lymphoid tissue: a European Mantle Cell Lymphoma Network study. *HemaSphere*. 2019;4(1):e302.

114. Castellino A, Tun AM, Wang Y, et al. Clinical characteristics and outcomes of primary versus secondary gastrointestinal mantle cell lymphoma. *Blood Cancer J*. 2021;11(1):8.

115. Kumar A, Ying Z, Alperovich A, et al. Clinical presentation determines selection of patients for initial observation in mantle cell lymphoma. *Haematologica*. 2019; 104(4):e163-e166.

116. Durani U, Ansell SM. CD5$^+$ diffuse large B-cell lymphoma: a narrative review. *Leuk Lymphoma*. 2021;62(13):3078-3086.

117. Hu B, Nastoupil LJ, Loghavi S, et al. *De novo* CD5$^+$ diffuse large B-cell lymphoma, NOS: clinical characteristics and outcomes in rituximab era. *Leuk Lymphoma*. 2020; 61(2):328-336.

118. Tzankov A, Leu N, Muenst S, et al. Multiparameter analysis of homogeneously R-CHOP-treated diffuse large B cell lymphomas identifies CD5 and FOXP1 as relevant prognostic biomarkers: report of the prospective SAKK 38/07 study. *J Hematol Oncol*. 2015;8(1):70.

119. Xu-Monette ZY, Tu M, Jabbar KJ, et al. Clinical and biological significance of de novo CD5$^+$ diffuse large B-cell lymphoma in Western countries. *Oncotarget*. 2015; 6(8):5615-5633.

120. Meriranta L, Pasanen A, Alkodsi A, Haukka J, Karjalainen-Lindsberg ML, Leppä S. Molecular background delineates outcome of double protein expressor diffuse large B-cell lymphoma. *Blood Adv*. 2020;4(15): 3742-3753.

121. Staiger AM, Ziepert M, Horn H, et al; German High-Grade Lymphoma Study Group. Clinical impact of the cell-of-origin classification and the MYC/ BCL2 dual expresser status in diffuse large B-cell lymphoma treated within prospective clinical trials of the German High-Grade Non-Hodgkin's Lymphoma Study Group. *J Clin Oncol*. 2017;35(22):2515-2526.

122. Bartlett NL, Wilson WH, Jung SH, et al. Dose-adjusted EPOCH-R compared with R-CHOP as frontline therapy for diffuse large B-cell lymphoma: Clinical outcomes of the phase III Intergroup Trial Alliance/ CALGB 50303. *J Clin Oncol*. 2019;37(21): 1790-1799.

123. Rosenwald A, Wright G, Chan WC, et al; Lymphoma/Leukemia Molecular Profiling Project. The use of molecular profiling to predict survival after chemotherapy for diffuse large-B-cell lymphoma. *N Engl J Med*. 2002;346(25):1937-1947.

124. Wright G, Tan B, Rosenwald A, Hurt EH, Wiestner A, Staudt LM. A gene expression-based method to diagnose clinically distinct subgroups of diffuse large B cell lymphoma. *Proc Natl Acad Sci USA*. 2003;100( 17):9991-9996.

125. Leonard JP, Kolibaba KS, Reeves JA, et al. Randomized phase II study of R-CHOP with or without bortezomib in previously untreated patients with non-germinal center B-cell-like diffuse large B-cell lymphoma. *J Clin Oncol*. 2017;35(31): 3538-3546.

126. Nowakowski GS, Chiappella A, Gascoyne RD, et al. ROBUST: a phase III study of lenalidomide plus R-CHOP versus placebo plus R-CHOP in previously untreated patients with ABC-type diffuse large B-cell lymphoma. *J Clin Oncol*. 2021;39(12): 1317-1328.

127. Nowakowski GS, Hong F, Scott DW, et al. Addition of lenalidomide to R-CHOP improves outcomes in newly diagnosed diffuse large B-cell lymphoma in a randomized phase II US Intergroup Study ECOG-ACRIN E1412. *J Clin Oncol*. 2021;39(12): 1329-1338.

128. Younes A, Sehn LH, Johnson P, et al; PHOENIX investigators. Randomized phase III trial of ibrutinib and rituximab plus cyclophosphamide, doxorubicin, vincristine, and prednisone in non-germinal center B-cell diffuse large B-cell lymphoma. *J Clin Oncol*. 2019;37(15):1285-1295.

129. Wilson WH, Wright GW, Huang DW, et al. Effect of ibrutinib with R-CHOP chemotherapy in genetic subtypes of DLBCL. *Cancer Cell*. 2021;39(12):1643-1653.e3.

130. Davies A, Cummin TE, Barrans S, et al. Gene-expression profiling of bortezomib added to standard chemoimmunotherapy for diffuse large B-cell lymphoma (REMoDL-B): an open-label, randomised, phase 3 trial. *Lancet Oncol*. 2019;20(5): 649-662.

131. Chapuy B, Stewart C, Dunford AJ, et al. Molecular subtypes of diffuse large B cell lymphoma are associated with distinct pathogenic mechanisms and outcomes. *Nat Med*. 2018;24(5):679-690.

132. Schmitz R, Wright GW, Huang DW, et al. Genetics and pathogenesis of diffuse large B-cell lymphoma. *N Engl J Med*. 2018; 378(15):1396-1407.

133. Wright GW, Huang DW, Phelan JD, et al. A probabilistic classification tool for genetic subtypes of diffuse large B cell lymphoma with therapeutic implications. *Cancer Cell*. 2020;37(4):551-568.e14.

134. Lacy SE, Barrans SL, Beer PA, et al. Targeted sequencing in DLBCL, molecular subtypes, and outcomes: a Haematological Malignancy Research Network report. *Blood*. 2020;135(20):1759-1771.

135. Morin RD, Arthur SE, Hodson DJ. Molecular profiling in diffuse large B-cell lymphoma: why so many types of subtypes? *Br J Haematol*. 2022;196(4): 814-829. doi: .

136. Pham-Ledard A, Beylot-Barry M, Barbe C, et al. High frequency and clinical prognostic value of MYD88 L265P mutation in primary cutaneous diffuse large B-cell lymphoma, leg-type. *JAMA Dermatol*. 2014;150(11):1173-1179.

137. Taniguchi K, Takata K, Chuang SS, et al. Frequent MYD88 L265P and CD79B mutations in primary breast diffuse large B-cell lymphoma. *Am J Surg Pathol*. 2016; 40(3):324-334.

138. Schrader AMR, Jansen PM, Willemze R, et al. High prevalence of *MYD88* and *CD79B* mutations in intravascular large B-cell lymphoma. *Blood*. 2018;131(18): 2086-2089.

139. Kraan W, van Keimpema M, Horlings HM, et al. High prevalence of oncogenic MYD88 and CD79B mutations in primary testicular diffuse large B-cell lymphoma. *Leukemia*. 2014;28(3):719-720.

140. Nakamura T, Tateishi K, Niwa T, et al. Recurrent mutations of CD79B and MYD88 are the hallmark of primary central nervous system lymphomas. *Neuropathol Appl Neurobiol*. 2016;42(3):279-290.

141. Horn H, Kalmbach S, Wagener R, et al. A diagnostic approach to the identification of Burkitt-like lymphoma with 11q aberration in aggressive B-cell lymphomas. *Am J Surg Pathol*. 2021;45(3):356-364.

142. Gebauer N, Witte HM, Merz H, et al. Aggressive B-cell lymphoma cases with 11q aberration patterns indicate a spectrum beyond Burkitt-like lymphoma. *Blood Adv*. 2021;5(23):5220-5225.

143. Au-Yeung RKH, Arias Padilla L, Zimmermann M, et al. Experience with provisional WHO-entities large B-cell lymphoma with IRF4-rearrangement and Burkitt-like lymphoma with 11q aberration in paediatric patients of the NHL-BFM group. *Br J Haematol*. 2020;190(5): 753-763.

144. Gonzalez-Farre B, Ramis-Zaldivar JE, Salmeron-Villalobos J, et al. Burkitt-like lymphoma with 11q aberration: a germinal

Downloaded from ashpublications.org/blood/article-pdf/140/11/1229/1921035/bloodbld2022015851c.pdf by guest on 15 September 2026

center-derived lymphoma genetically unrelated to Burkitt lymphoma. *Haematologica*. 2019;104(9):1822-1829.

145. Wagener R, Seufert J, Raimondi F, et al. The mutational landscape of Burkitt-like lymphoma with 11q aberration is distinct from that of Burkitt lymphoma. *Blood*. 2019;133(9):962-966.

146. Kaji D, Ota Y, Sato Y, et al. Primary human herpesvirus 8-negative effusion-based lymphoma: a large B-cell lymphoma with favorable prognosis. *Blood Adv*. 2020;4(18): 4442-4450.

147. Kubota T, Sasaki Y, Shiozawa E, Takimoto M, Hishima T, Chong JM. Age and CD20 expression are significant prognostic factors in human herpes virus-8-negative effusion-based lymphoma. *Am J Surg Pathol*. 2018;42(12):1607-1616.

148. Alexanian S, Said J, Lones M, Pullarkat ST. KSHV/HHV8-negative effusion-based lymphoma, a distinct entity associated with fluid overload states. *Am J Surg Pathol*. 2013;37(2):241-249.

149. Natkunam Y, Goodlad JR, Chadburn A, et al. EBV-positive B-cell proliferations of varied malignant potential: 2015 SH/EAHP Workshop Report-Part 1. *Am J Clin Pathol*. 2017;147(2):129-152.

150. Natkunam Y, Gratzinger D, Chadburn A, et al. Immunodeficiency-associated lymphoproliferative disorders: time for reappraisal? *Blood*. 2018;132(18): 1871-1878.

151. Oyama T, Yamamoto K, Asano N, et al. Age-related EBV-associated B-cell lymphoproliferative disorders constitute a distinct clinicopathologic group: a study of 96 patients. *Clin Cancer Res*. 2007;13(17): 5124-5132.

152. Nicolae A, Pittaluga S, Abdullah S, et al. EBV-positive large B-cell lymphomas in young patients: a nodal lymphoma with evidence for a tolerogenic immune environment. *Blood*. 2015;126(7):863-872.

153. Hong JY, Yoon DH, Suh C, et al. EBV-positive diffuse large B-cell lymphoma in young adults: is this a distinct disease entity? *Ann Oncol*. 2015;26(3):548-555.

154. Bourbon E, Maucort-Boulch D, Fontaine J, et al. Clinicopathological features and survival in EBV-positive diffuse large B-cell lymphoma not otherwise specified. *Blood Adv*. 2021;5(16):3227-3239.

155. Hofscheier A, Ponciano A, Bonzheim I, et al. Geographic variation in the prevalence of Epstein-Barr virus-positive diffuse large B-cell lymphoma of the elderly: a comparative analysis of a Mexican and a German population. *Mod Pathol*. 2011;24(8):1046-1054.

156. Dojcinov SD, Venkataraman G, Pittaluga S, et al. Age-related EBV-associated lymphoproliferative disorders in the Western population: a spectrum of reactive lymphoid hyperplasia and lymphoma. *Blood*. 2011; 117(18):4726-4735.

157. Asano N, Yamamoto K, Tamaru J, et al. Age-related Epstein-Barr virus (EBV)-associated B-cell lymphoproliferative disorders: comparison with EBV-positive classic Hodgkin lymphoma in elderly patients. *Blood*. 2009;113(12):2629-2636.

158. Dojcinov SD, Venkataraman G, Raffeld M, Pittaluga S, Jaffe ES. EBV positive mucocutaneous ulcer–a study of 26 cases associated with various sources of immunosuppression. *Am J Surg Pathol*. 2010;34(3):405-417.

159. Dojcinov SD, Fend F, Quintanilla-Martinez L. EBV-positive lymphoproliferations of B- T- and NK-cell derivation in non-immunocompromised hosts. *Pathogens*. 2018;7(1):28.

160. Ikeda T, Gion Y, Sakamoto M, et al. Clinicopathological analysis of 34 Japanese patients with EBV-positive mucocutaneous ulcer. *Mod Pathol*. 2020;33(12):2437-2448.

161. Yamakawa N, Fujimoto M, Kawabata D, et al. A clinical, pathological, and genetic characterization of methotrexate-associated lymphoproliferative disorders. *J Rheumatol*. 2014;41(2):293-299.

162. Melani C, Jaffe ES, Wilson WH. Pathobiology and treatment of lymphomatoid granulomatosis, a rare EBV-driven disorder. *Blood*. 2020;135(16): 1344-1352.

163. Colby TV. Current histological diagnosis of lymphomatoid granulomatosis. *Mod Pathol*. 2012;25(suppl 1):S39-S42.

164. Kim JY, Jung KC, Park SH, Choe JY, Kim JE. Primary lymphomatoid granulomatosis in the central nervous system: a report of three cases. *Neuropathology*. 2018;38(4): 331-336.

165. Xiang Y, Liu C, Xue Y, et al. Primary central nervous system lymphomatoid granulomatosis: systemic review. *Front Neurol*. 2020;11:901.

166. Cesarman E, Chadburn A, Rubinstein PG. KSHV/HHV8-mediated hematologic diseases. *Blood*. 2021;139(7):1013-1025.

167. Lurain K, Polizzotto MN, Aleman K, et al. Viral, immunologic, and clinical features of primary effusion lymphoma. *Blood*. 2019; 133(16):1753-1761.

168. Simonelli C, Spina M, Cinelli R, et al. Clinical features and outcome of primary effusion lymphoma in HIV-infected patients: a single-institution study. *J Clin Oncol*. 2003;21(21):3948-3954.

169. Doble A, Thomas BJ, Furr PM, et al. A search for infectious agents in chronic abacterial prostatitis using ultrasound guided biopsy. *Br J Urol*. 1989;64(3): 297-301.

170. Aguilar C, Laberiano C, Beltran B, Diaz C, Taype-Rondan A, Castillo JJ. Clinicopathologic characteristics and survival of patients with primary effusion lymphoma. *Leuk Lymphoma*. 2020;61(9): 2093-2102.

171. Du MQ, Liu H, Diss TC, et al. Kaposi sarcoma-associated herpesvirus infects monotypic (IgM lambda) but polyclonal naive B cells in Castleman disease and associated lymphoproliferative disorders. *Blood*. 2001;97(7):2130-2136.

172. Cucco F, Barrans S, Sha C, et al. Distinct genetic changes reveal evolutionary history and heterogeneous molecular grade of DLBCL with MYC/BCL2 double-hit. *Leukemia*. 2020;34(5):1329-1341.

173. Evrard SM, Péricart S, Grand D, et al. Targeted next generation sequencing reveals high mutation frequency of *CREBBP*, *BCL2* and *KMT2D* in high-grade B-cell lymphoma with *MYC* and *BCL2* and/or *BCL6* rearrangements. *Haematologica*. 2019;104(4):e154-e157.

174. Künstner A, Witte HM, Riedl J, et al. Mutational landscape of high-grade B-cell lymphoma with *MYC*-, *BCL2* and/or *BCL6* rearrangements characterized by whole-exome sequencing. *Haematologica*. 2022; 107(8):1850-1863.

175. Ennishi D, Jiang A, Boyle M, et al. Double-hit gene expression signature defines a distinct subgroup of germinal center B-cell-like diffuse large B-cell lymphoma. *J Clin Oncol*. 2019;37(3):190-201.

176. Sha C, Barrans S, Cucco F, et al. Molecular high-grade B-cell lymphoma: defining a poor-risk group that requires different approaches to therapy. *J Clin Oncol*. 2019; 37(3):202-212.

177. Hilton LK, Tang J, Ben-Neriah S, et al. The double-hit signature identifies double-hit diffuse large B-cell lymphoma with genetic events cryptic to FISH. *Blood*. 2019; 134(18):1528-1532.

178. Li S, Desai P, Lin P, et al. MYC/BCL6 double-hit lymphoma (DHL): a tumour associated with an aggressive clinical course and poor prognosis. *Histopathology*. 2016;68(7):1090-1098.

179. Pillai RK, Sathanoori M, Van Oss SB, Swerdlow SH. Double-hit B-cell lymphomas with *BCL6* and *MYC* translocations are aggressive, frequently extranodal lymphomas distinct from *BCL2* double-hit B-cell lymphomas. *Am J Surg Pathol*. 2013;37(3): 323-332.

180. Rosenwald A, Bens S, Advani R, et al. Prognostic significance of *MYC* rearrangement and translocation partner in diffuse large B-cell lymphoma: a study by the Lunenburg Lymphoma Biomarker Consortium. *J Clin Oncol*. 2019;37(35): 3359-3368.

181. Ye Q, Xu-Monette ZY, Tzankov A, et al. Prognostic impact of concurrent MYC and BCL6 rearrangements and expression in de novo diffuse large B-cell lymphoma. *Oncotarget*. 2016;7(3):2401-2416.

182. Johnson SM, Umakanthan JM, Yuan J, et al. Lymphomas with pseudo-double-hit BCL6-MYC translocations due to t(3;8)(q27;q24) are associated with a germinal center immunophenotype, extranodal involvement, and frequent BCL2 translocations. *Hum Pathol*. 2018;80:192-200.

183. Collinge B, Ben-Neriah S, Chong L, et al. The impact of MYC and BCL2 structural variants in tumors of DLBCL morphology

Downloaded from ashpublications.org/blood/article-pdf/140/11/1229/1921035/bloodbld2022015851c.pdf by guest on 15 September 2026

and mechanisms of false-negative MYC IHC. *Blood*. 2021;137(16):2196-2208.

184. Li S, Seegmiller AC, Lin P, et al. B-cell lymphomas with concurrent MYC and BCL2 abnormalities other than translocations behave similarly to MYC/BCL2 double-hit lymphomas. *Mod Pathol*. 2015;28(2): 208-217.

185. Schieppati F, Balzarini P, Fisogni S, et al. An increase in *MYC* copy number has a progressive negative prognostic impact in patients with diffuse large B-cell and high-grade lymphoma, who may benefit from intensified treatment regimens. *Haematologica*. 2020;105(5):1369-1378.

186. Landsburg DJ, Falkiewicz MK, Petrich AM, et al. Sole rearrangement but not amplification of MYC is associated with a poor prognosis in patients with diffuse large B cell lymphoma and B cell lymphoma unclassifiable. *Br J Haematol*. 2016;175(4):631-640.

187. Copie-Bergman C, Cuillière-Dartigues P, Baia M, et al. MYC-IG rearrangements are negative predictors of survival in DLBCL patients treated with immunochemotherapy: a GELA/LYSA study. *Blood*. 2015;126(22):2466-2474.

188. McPhail ED, Maurer MJ, Macon WR, et al. Inferior survival in high-grade B-cell lymphoma with *MYC* and *BCL2* and/or *BCL6* rearrangements is not associated with *MYC/IG* gene rearrangements. *Haematologica*. 2018;103(11):1899-1907.

189. Collinge BJ, Hilton LK, Wong J, et al. Characterization of the genetic landscape of high-grade B-cell lymphoma, NOS – an LLMPP project. *Hematol Oncol*. 2021; 39(S2).

190. Hüttl KS, Staiger AM, Richter J, et al. The "Burkitt-like" immunophenotype and genotype is rarely encountered in diffuse large B cell lymphoma and high-grade B cell lymphoma, NOS. *Virchows Arch*. 2021;479(3): 575-583.

191. Bhavsar S, Liu YC, Gibson SE, Moore EM, Swerdlow SH. Mutational landscape of $TdT^{+}$ large B-cell lymphomas supports their distinction from B-lymphoblastic neoplasms. A multiparameter study of a rare and aggressive entity. *Am J Surg Pathol*. 2022;46(1):71-82.

192. Luchtel RA, Zimmermann MT, Hu G, et al. Recurrent *MSC* $^{E116K}$ mutations in ALK-negative anaplastic large cell lymphoma. *Blood*. 2019;133(26):2776-2789.

193. Khanlari M, Medeiros LJ, Lin P, et al. Blastoid high-grade B-cell lymphoma initially presenting in bone marrow: a diagnostic challenge. *Mod Pathol*. 2022;35(3): 419-426.

194. Nie K, Redmond D, Eng KW, et al. Mutation landscape, clonal evolution pattern, and potential pathogenic pathways in B-lymphoblastic transformation of follicular lymphoma. *Leukemia*. 2021;35(4):1203-1208.

195. Wagener R, López C, Kleinheinz K, et al. IG-*MYC* $^{+}$ neoplasms with precursor B-cell phenotype are molecularly distinct from Burkitt lymphomas. *Blood*. 2018;132(21): 2280-2285.

196. Navid F, Mosijczuk AD, Head DR, et al. Acute lymphoblastic leukemia with the (8;14)(q24;q32) translocation and FAB L3 morphology associated with a B-precursor immunophenotype: the Pediatric Oncology Group experience. *Leukemia*. 1999;13(1): 135-141.

197. Arber DA, Orazi A, Hasserjian RP, et al. International Consensus Classification of myeloid neoplasms and acute leukemia: integrating morphological, clinical, and genomic data. *Blood*. 2022;140(11): 1200-1228.

198. Hartmann S, Eichenauer DA. Nodular lymphocyte predominant Hodgkin lymphoma: pathology, clinical course and relation to T-cell/histiocyte rich large B-cell lymphoma. *Pathology*. 2020;52(1):142-153.

199. Fan Z, Natkunam Y, Bair E, Tibshirani R, Warnke RA. Characterization of variant patterns of nodular lymphocyte predominant hodgkin lymphoma with immunohistologic and clinical correlation. *Am J Surg Pathol*. 2003;27(10):1346-1356.

200. Hartmann S, Eichenauer DA, Plütschow A, et al. The prognostic impact of variant histology in nodular lymphocyte-predominant Hodgkin lymphoma: a report from the German Hodgkin Study Group (GHSG). *Blood*. 2013;122(26):4246-4252.

201. Huppmann AR, Nicolae A, Slack GW, et al. EBV may be expressed in the LP cells of nodular lymphocyte-predominant Hodgkin lymphoma (NLPHL) in both children and adults. *Am J Surg Pathol*. 2014;38(3): 316-324.

202. Wilson WH, Pittaluga S, Nicolae A, et al. A prospective study of mediastinal gray-zone lymphoma. *Blood*. 2014;124(10): 1563-1569.

203. Pittaluga S, Nicolae A, Wright GW, et al. Gene expression profiling of mediastinal gray zone lymphoma and its relationship to primary mediastinal B-cell lymphoma and classical Hodgkin lymphoma. *Blood Cancer Discov*. 2020;1(2):155-161.

204. Chapuy B, Stewart C, Dunford AJ, et al. Genomic analyses of PMBL reveal new drivers and mechanisms of sensitivity to PD-1 blockade. *Blood*. 2019;134(26): 2369-2382.

205. Sarkozy C, Hung SS, Chavez EA, et al. Mutational landscape of gray zone lymphoma. *Blood*. 2021;137(13): 1765-1776.

206. Quintanilla-Martinez L, Ridaura C, Nagl F, et al. Hydroa vacciniforme-like lymphoma: a chronic EBV+ lymphoproliferative disorder with risk to develop a systemic lymphoma. *Blood*. 2013;122(18):3101-3110.

207. Cohen JI, Iwatsuki K, Ko YH, et al. Epstein-Barr virus NK and T cell lymphoproliferative disease: report of a 2018 international meeting. *Leuk Lymphoma*. 2020;61(4): 808-819.

208. Cohen JI, Manoli I, Dowdell K, et al. Hydroa vacciniforme-like lymphoproliferative disorder: an EBV disease with a low risk of systemic illness in whites. *Blood*. 2019;133(26):2753-2764.

209. Miyake T, Yamamoto T, Hirai Y, et al. Survival rates and prognostic factors of Epstein-Barr virus-associated hydroa vacciniforme and hypersensitivity to mosquito bites. *Br J Dermatol*. 2015;172(1):56-63.

210. Barrionuevo C, Anderson VM, Zevallos-Giampietri E, et al. Hydroa-like cutaneous T-cell lymphoma: a clinicopathologic and molecular genetic study of 16 pediatric cases from Peru. *Appl Immunohistochem Mol Morphol*. 2002;10(1):7-14.

211. Rodríguez-Pinilla SM, Barrionuevo C, García J, et al. Epstein-Barr virus-positive systemic NK/T-cell lymphomas in children: report of six cases. *Histopathology*. 2011; 59(6):1183-1193.

212. Bollard CM, Cohen JI. How I treat T-cell chronic active Epstein-Barr virus disease. *Blood*. 2018;131(26):2899-2905.

213. Kimura H, Ito Y, Kawabe S, et al. EBV-associated T/NK-cell lymphoproliferative diseases in nonimmunocompromised hosts: prospective analysis of 108 cases. *Blood*. 2012;119(3):673-686.

214. Kimura H, Cohen JI. Chronic active Epstein-Barr virus disease. *Front Immunol*. 2017;8:1867.

215. Yonese I, Sakashita C, Imadome KI, et al. Nationwide survey of systemic chronic active EBV infection in Japan in accordance with the new WHO classification. *Blood Adv*. 2020;4(13):2918-2926.

216. Cohen JI. Primary immunodeficiencies associated with EBV disease. *Curr Top Microbiol Immunol*. 2015;390(pt 1): 241-265.

217. Plaza JA, Sangueza M. Hydroa vacciniforme-like lymphoma with primarily periorbital swelling: 7 cases of an atypical clinical manifestation of this rare cutaneous T-cell lymphoma. *Am J Dermatopathol*. 2015;37(1):20-25.

218. Okuno Y, Murata T, Sato Y, et al. Defective Epstein-Barr virus in chronic active infection and haematological malignancy. *Nat Microbiol*. 2019;4(3):404-413.

219. Kato S, Yamashita D, Nakamura S. Nodal EBV+ cytotoxic T-cell lymphoma: a literature review based on the 2017 WHO classification. *J Clin Exp Hematop*. 2020;60(2): 30-36.

220. Attygalle AD, Cabeçadas J, Gaulard P, et al. Peripheral T-cell and NK-cell lymphomas and their mimics; taking a step forward - report on the lymphoma workshop of the XVIth meeting of the European Association for Haematopathology and the Society for Hematopathology. *Histopathology*. 2014; 64(2):171-199.

221. Kato S, Asano N, Miyata-Takata T, et al. T-cell receptor (TCR) phenotype of nodal Epstein-Barr virus (EBV)-positive cytotoxic T-cell lymphoma (CTL): a clinicopathologic study of 39 cases. *Am J Surg Pathol*. 2015; 39(4):462-471.

Downloaded from ashpublications.org/blood/article-pdf/140/11/1229/1921035/bloodbld2022015851c.pdf by guest on 15 September 2026

222. Ng SB, Chung TH, Kato S, et al. Epstein-Barr virus-associated primary nodal T/NK-cell lymphoma shows a distinct molecular signature and copy number changes. *Haematologica*. 2018;103(2):278-287.

223. Wai CMM, Chen S, Phyu T, et al. Immune pathway upregulation and lower genomic instability distinguish EBV-positive nodal T/NK-cell lymphoma from ENKTL and PTCL-NOS [published online ahead of print 13 January 2022]. *Haematologica*. doi:10.3324/haematol.2021.280003.

224. Jaffe ES. T-cell and NK-cell neoplasms of the gastrointestinal tract – recurrent themes, but clinical and biological distinctions exist. *Haematologica*. 2020;105(7): 1760-1762.

225. Mutzbauer G, Maurus K, Buszello C, et al. SYK expression in monomorphic epitheliotropic intestinal T-cell lymphoma. *Mod Pathol*. 2018;31(3):505-516.

226. Chan JK, Chan AC, Cheuk W, et al. Type II enteropathy-associated T-cell lymphoma: a distinct aggressive lymphoma with frequent γδ T-cell receptor expression. *Am J Surg Pathol*. 2011;35(10):1557-1569.

227. Tan SY, Nakamura S, Tan HC, Liu YH, Chuang SS. Diagnosis of type II enteropathy-associated T-cell lymphoma should be limited to EBER-cases. *Am J Hematol*. 2012;87(11):E129-E130.

228. Veloza L, Cavalieri D, Missiglia E, et al. Monomorphic epitheliotropic intestinal T-cell lymphoma comprises morphologic and genomic heterogeneity impacting outcome. *Haematologica*. 2022. doi: 10.3324/haematol.2022.281226.

229. Moffitt AB, Ondrejka SL, McKinney M, et al. Enteropathy-associated T cell lymphoma subtypes are characterized by loss of function of SETD2. *J Exp Med*. 2017;214(5):1371-1386.

230. Sallak A, Besson FL, Pomoni A, et al. Conjunctival MALT lymphoma: utility of FDG PET/CT for diagnosis, staging, and evaluation of treatment response. *Clin Nucl Med*. 2014;39(3):295-297.

231. Küçük C, Jiang B, Hu X, et al. Activating mutations of STAT5B and STAT3 in lymphomas derived from γδ-T or NK cells. *Nat Commun*. 2015;6(1):6025.

232. Tomita S, Kikuti YY, Carreras J, et al. Monomorphic epitheliotropic intestinal T-cell lymphoma in asia frequently shows *SETD2* alterations. *Cancers (Basel)*. 2020; 12(12):3539.

233. Roberti A, Dobay MP, Bisig B, et al. Type II enteropathy-associated T-cell lymphoma features a unique genomic profile with highly recurrent SETD2 alterations. *Nat Commun*. 2016;7(1):12602.

234. Cording S, Lhermitte L, Malamut G, et al. Oncogenetic landscape of lymphomagenesis in coeliac disease. *Gut*. 2022;71(3):497-508.

235. Soderquist CR, Lewis SK, Gru AA, et al. Immunophenotypic spectrum and genomic landscape of refractory celiac disease type II. *Am J Surg Pathol*. 2021;45(7):905-916.

236. Xiao W, Gupta GK, Yao J, et al. Recurrent somatic *JAK3* mutations in NK-cell enteropathy. *Blood*. 2019;134(12):986-991.

237. Mansoor A, Pittaluga S, Beck PL, Wilson WH, Ferry JA, Jaffe ES. NK-cell enteropathy: a benign NK-cell lymphoproliferative disease mimicking intestinal lymphoma: clinicopathologic features and follow-up in a unique case series. *Blood*. 2011;117(5):1447-1452.

238. Dargent JL, Tinton N, Trimech M, de Leval L. Lymph node involvement by enteropathy-like indolent NK-cell proliferation. *Virchows Arch*. 2021;478(6): 1197-1202.

239. Perry AM, Warnke RA, Hu Q, et al. Indolent T-cell lymphoproliferative disease of the gastrointestinal tract. *Blood*. 2013;122(22): 3599-3606.

240. Soderquist CR, Patel N, Murty VV, et al. Genetic and phenotypic characterization of indolent T-cell lymphoproliferative disorders of the gastrointestinal tract. *Haematologica*. 2020;105(7):1895-1906.

241. Sharma A, Oishi N, Boddicker RL, et al. Recurrent *STAT3-JAK2* fusions in indolent T-cell lymphoproliferative disorder of the gastrointestinal tract. *Blood*. 2018;131(20): 2262-2266.

242. Montes-Moreno S, King RL, Oschlies I, et al. Update on lymphoproliferative disorders of the gastrointestinal tract: disease spectrum from indolent lymphoproliferations to aggressive lymphomas. *Virchows Arch*. 2020;476(5): 667-681.

243. Takeuchi K, Yokoyama M, Ishizawa S, et al. Lymphomatoid gastropathy: a distinct clinicopathologic entity of self-limited pseudomalignant NK-cell proliferation. *Blood*. 2010;116(25):5631-5637.

244. Heavican TB, Bouska A, Yu J, et al. Genetic drivers of oncogenic pathways in molecular subgroups of peripheral T-cell lymphoma. *Blood*. 2019;133(15):1664-1676.

245. Iqbal J, Wright G, Wang C, et al; Lymphoma Leukemia Molecular Profiling Project and the International Peripheral T-cell Lymphoma Project. Gene expression signatures delineate biological and prognostic subgroups in peripheral T-cell lymphoma. *Blood*. 2014;123(19):2915-2923.

246. de Leval L, Gaulard P. Cellular origin of T-cell lymphomas. *Blood*. 2014;123(19): 2909-2910.

247. Amador C, Greiner TC, Heavican TB, et al. Reproducing the molecular subclassification of peripheral T-cell lymphoma-NOS by immunohistochemistry. *Blood*. 2019;134(24):2159-2170.

248. Nicolae A, Bouilly J, Lara D, et al. Nodal cytotoxic peripheral T-cell lymphoma occurs frequently in the clinical setting of immunodysregulation and is associated with recurrent epigenetic alterations [published online ahead of print 17 March 2022]. *Mod Pathol*. doi:10.1038/s41379-022-01022-w.

249. de Leval L, Rickman DS, Thielen C, et al. The gene expression profile of nodal peripheral T-cell lymphoma demonstrates a molecular link between angioimmunoblastic T-cell lymphoma (AITL) and follicular helper T (TFH) cells. *Blood*. 2007;109(11): 4952-4963.

250. Piccaluga PP, Agostinelli C, Califano A, et al. Gene expression analysis of angioimmunoblastic lymphoma indicates derivation from T follicular helper cells and vascular endothelial growth factor deregulation. *Cancer Res*. 2007;67(22): 10703-10710.

251. Dobay MP, Lemonnier F, Missiaglia E, et al. Integrative clinicopathological and molecular analyses of angioimmunoblastic T-cell lymphoma and other nodal lymphomas of follicular helper T-cell origin. *Haematologica*. 2017;102(4):e148-e151.

252. Basha BM, Bryant SC, Rech KL, et al. Application of a 5 marker panel to the routine diagnosis of peripheral T-cell lymphoma with T-follicular helper phenotype. *Am J Surg Pathol*. 2019;43(9):1282-1290.

253. Steinhilber J, Mederake M, Bonzheim I, et al. The pathological features of angioimmunoblastic T-cell lymphomas with $IDH2^{R172}$ mutations. *Mod Pathol*. 2019; 32(8):1123-1134.

254. Rodríguez M, Alonso-Alonso R, Tomás-Roca L, et al. Peripheral T-cell lymphoma: molecular profiling recognizes subclasses and identifies prognostic markers. *Blood Adv*. 2021;5(24):5588-5598.

255. Vallois D, Dobay MP, Morin RD, et al. Activating mutations in genes related to TCR signaling in angioimmunoblastic and other follicular helper T-cell-derived lymphomas. *Blood*. 2016;128(11): 1490-1502.

256. Drieux F, Ruminy P, Sater V, et al. Detection of gene fusion transcripts in peripheral T-cell lymphoma using a multiplexed targeted sequencing assay. *J Mol Diagn*. 2021;23(8):929-940.

257. Falchi L, Ma H, Klein S, et al. Combined oral 5-azacytidine and romidepsin are highly effective in patients with PTCL: a multicenter phase 2 study [published correction appears in Blood 2022;139(10):1600]. *Blood*. 2021; 137(16):2161-2170.

258. Lemonnier F, Dupuis J, Sujobert P, et al. Treatment with 5-azacytidine induces a sustained response in patients with angioimmunoblastic T-cell lymphoma. *Blood*. 2018; 132(21):2305-2309.

259. Ghione P, Faruque P, Mehta-Shah N, et al. T follicular helper phenotype predicts response to histone deacetylase inhibitors in relapsed/refractory peripheral T-cell lymphoma. *Blood Adv*. 2020;4(19):4640-4647.

260. Beltzung F, Ortonne N, Pelletier L, et al. Primary cutaneous $CD4^+$ small/medium T-cell lymphoproliferative disorders: a clinical, pathologic, and molecular study of 60 cases presenting with a single lesion: a multicenter study of the French Cutaneous Lymphoma Study Group. *Am J Surg Pathol*. 2020;44(7):862-872.

Downloaded from ashpublications.org/blood/article-pdf/140/11/1229/1921035/bloodbld2022015851c.pdf by guest on 15 September 2026

261. Syrykh C, Gorez P, Péricart S, et al. Molecular diagnosis of T-cell lymphoma: a correlative study of PCR-based T-cell clonality assessment and targeted NGS. *Blood Adv*. 2021;5(22):4590-4593.

262. Parrilla Castellar ER, Jaffe ES, Said JW, et al. ALK-negative anaplastic large cell lymphoma is a genetically heterogeneous disease with widely disparate clinical outcomes. *Blood*. 2014;124(9):1473-1480.

263. King RL, Dao LN, McPhail ED, et al. Morphologic features of ALK-negative anaplastic large cell lymphomas with DUSP22 rearrangements. *Am J Surg Pathol*. 2016; 40(1):36-43.

264. Luchtel RA, Dasari S, Oishi N, et al. Molecular profiling reveals immunogenic cues in anaplastic large cell lymphomas with *DUSP22* rearrangements. *Blood*. 2018; 132(13):1386-1398.

265. Hapgood G, Ben-Neriah S, Mottok A, et al. Identification of high-risk DUSP22-rearranged ALK-negative anaplastic large cell lymphoma. *Br J Haematol*. 2019;186(3): e28-e31.

266. Onaindia A, de Villambrosía SG, Prieto-Torres L, et al. *DUSP22*-rearranged anaplastic lymphomas are characterized by specific morphological features and a lack of cytotoxic and JAK/STAT surrogate markers. *Haematologica*. 2019;104(4): e158-e162.

267. Pedersen MB, Hamilton-Dutoit SJ, Bendix K, et al. *DUSP22* and *TP63* rearrangements predict outcome of ALK-negative anaplastic large cell lymphoma: a Danish cohort study. *Blood*. 2017;130(4):554-557.

268. Karube K, Feldman AL. "Double-hit" of DUSP22 and TP63 rearrangements in anaplastic large cell lymphoma, ALK-negative. *Blood*. 2020;135(9):700.

269. Fitzpatrick MJ, Massoth LR, Marcus C, et al. JAK2 rearrangements are a recurrent alteration in $CD30^+$ systemic T-cell lymphomas with anaplastic morphology. *Am J Surg Pathol*. 2021;45(7):895-904.

270. Jaffe ES, Ashar BS, Clemens MW, et al. Best practices guideline for the pathologic diagnosis of breast implant-associated anaplastic large-cell lymphoma. *J Clin Oncol*. 2020;38(10):1102-1111.

271. Laurent C, Nicolae A, Laurent C, et al. Gene alterations in epigenetic modifiers and JAK-STAT signaling are frequent in breast implant-associated ALCL. *Blood*. 2020;135(5):360-370.

272. Oishi N, Hundal T, Phillips JL, et al. Molecular profiling reveals a hypoxia signature in breast implant-associated anaplastic large cell lymphoma. *Haematologica*. 2021;106(6):1714-1724.

273. Di Napoli A, De Cecco L, Piccaluga PP, et al. Transcriptional analysis distinguishes breast implant-associated anaplastic large cell lymphoma from other peripheral T-cell lymphomas. *Mod Pathol*. 2019;32(2): 216-230.

274. Los-de Vries GT, de Boer M, van Dijk E, et al. Chromosome 20 loss is characteristic of breast implant-associated anaplastic large cell lymphoma. *Blood*. 2020;136(25): 2927-2932.

275. de Leval L. Chromosomes in breast lymphoma. *Blood*. 2020;136(25): 2848-2849.

276. Laurent C, Delas A, Gaulard P, et al. Breast implant-associated anaplastic large cell lymphoma: two distinct clinicopathological variants with different outcomes. *Ann Oncol*. 2016;27(2):306-314.

277. Clemens MW, Medeiros LJ, Butler CE, et al. Complete surgical excision is essential for the management of patients with breast implant-associated anaplastic large-cell lymphoma. *J Clin Oncol*. 2016; 34(2):160-168.

278. Lyapichev KA, Medeiros LJ, Clemens MW, et al. Reconsideration of the first recognition of breast implant-associated anaplastic large cell lymphoma: A critical review of the literature. *Ann Diagn Pathol*. 2020;45:151474.

279. Cerroni L, Signoretti S, Höfler G, et al. Primary cutaneous marginal zone B-cell lymphoma: a recently described entity of low-grade malignant cutaneous B-cell lymphoma. *Am J Surg Pathol*. 1997;21(11): 1307-1315.

280. Edinger JT, Kant JA, Swerdlow SH. Cutaneous marginal zone lymphomas have distinctive features and include 2 subsets. *Am J Surg Pathol*. 2010;34(12):1830-1841.

281. Willemze R, Cerroni L, Kempf W, et al. The 2018 update of the WHO-EORTC classification for primary cutaneous lymphomas. *Blood*. 2019;133(16):1703-1714.

282. Gibson SE, Swerdlow SH. How I diagnose primary cutaneous marginal zone lymphoma. *Am J Clin Pathol*. 2020;154(4): 428-449.

283. Fernandez-Flores A. Is there a narrow connection between the two subsets of cutaneous MALT lymphomas and the dynamics of the follicle? *Am J Dermatopathol*. 2013;35(2):283-284.

284. Guitart J. Rethinking primary cutaneous marginal zone lymphoma: shifting the focus to the cause of the infiltrate. *J Cutan Pathol*. 2015;42(9):600-603.

285. Carlsen ED, Swerdlow SH, Cook JR, Gibson SE. Class-switched primary cutaneous marginal zone lymphomas are frequently IgG4-positive and have features distinct from IgM-positive cases. *Am J Surg Pathol*. 2019;43(10):1403-1412.

286. van Maldegem F, van Dijk R, Wormhoudt TA, et al. The majority of cutaneous marginal zone B-cell lymphomas expresses class-switched immunoglobulins and develops in a T-helper type 2 inflammatory environment. *Blood*. 2008;112(8):3355-3361.

287. Carlsen ED, Bhavsar S, Cook JR, Swerdlow SH. IRTA1 positivity helps identify a MALT-lymphoma-like subset of primary cutaneous marginal zone lymphomas, largely but not exclusively defined by IgM expression. *J Cutan Pathol*. 2022;49(1):55-60.

288. Brenner I, Roth S, Puppe B, Wobser M, Rosenwald A, Geissinger E. Primary cutaneous marginal zone lymphomas with plasmacytic differentiation show frequent IgG4 expression. *Mod Pathol*. 2013;26(12): 1568-1576.

289. Maurus K, Appenzeller S, Roth S, et al. Panel sequencing shows recurrent genetic FAS alterations in primary cutaneous marginal zone lymphoma. *J Invest Dermatol*. 2018;138(7):1573-1581.

290. Barasch NJK, Liu YC, Ho J, et al. The molecular landscape and other distinctive features of primary cutaneous follicle center lymphoma. *Hum Pathol*. 2020;106: 93-105.

291. Zhou XA, Yang J, Ringbloom KG, et al. Genomic landscape of cutaneous follicular lymphomas reveals 2 subgroups with clinically predictive molecular features. *Blood Adv*. 2021;5(3):649-661.

292. Suehara Y, Sakata-Yanagimoto M, Hattori K, et al. Liquid biopsy for the identification of intravascular large B-cell lymphoma. *Haematologica*. 2018;103(6):e241-e244.

293. Shimada K, Yoshida K, Suzuki Y, et al. Frequent genetic alterations in immune checkpoint-related genes in intravascular large B-cell lymphoma. *Blood*. 2021; 137(11):1491-1502.

294. Ferreri AJ, Campo E, Seymour JF, et al; International Extranodal Lymphoma Study Group (IELSG). Intravascular lymphoma: clinical presentation, natural history, management and prognostic factors in a series of 38 cases, with special emphasis on the 'cutaneous variant'. *Br J Haematol*. 2004;127(2):173-183.

295. Ponzoni M, Campo E, Nakamura S. Intravascular large B-cell lymphoma: a chameleon with multiple faces and many masks. *Blood*. 2018;132(15):1561-1567.

296. Schrader AMR, de Groen RAL, Willemze R, et al. Cell-of-origin classification using the Hans and Lymph2Cx algorithms in primary cutaneous large B-cell lymphomas. *Virchows Arch*. 2022;480(3):667-675.

297. Endo M, Ohtsuka M, Watanabe Y, et al. TdT-positive primary cutaneous diffuse large B-cell lymphoma, leg type phenotypically mimicking B-lymphoblastic lymphoma. *J Cutan Pathol*. 2021;48(5):721-724.

298. Ronchi A, Zito Marino F, Vitiello P, et al. A case of primary cutaneous B-cell lymphoma with immature features in an old man. Diffuse large B-cell lymphoma with immature features or B-cell lymphoblastic lymphoma? *J Cutan Pathol*. 2021;48(4):535-540.

299. Gayden T, Sepulveda FE, Khuong-Quang DA, et al. Germline HAVCR2 mutations altering TIM-3 characterize subcutaneous panniculitis-like T cell lymphomas with hemophagocytic lymphohistiocytic syndrome. *Nat Genet*. 2018;50(12):1650-1657.

300. Polprasert C, Takeuchi Y, Kakiuchi N, et al. Frequent germline mutations of *HAVCR2* in sporadic subcutaneous panniculitis-like T-cell lymphoma. *Blood Adv*. 2019;3(4): 588-595.

Downloaded from ashpublications.org/blood/article-pdf/140/11/1229/1921035/bloodbld2022015851c.pdf by guest on 15 September 2026

301. Koh J, Jang I, Mun S, et al. Genetic profiles of subcutaneous panniculitis-like T-cell lymphoma and clinicopathological impact of HAVCR2 mutations. *Blood Adv.* 2021;5(20): 3919-3930.

302. Tensen CP, Quint KD, Vermeer MH. Genetic and epigenetic insights into cutaneous T-cell lymphoma. *Blood.* 2022; 139(1):15-33.

303. Beltraminelli H, Müllegger R, Cerroni L. Indolent CD8$^+$ lymphoid proliferation of the ear: a phenotypic variant of the small-medium pleomorphic cutaneous T-cell lymphoma? *J Cutan Pathol.* 2010;37(1): 81-84.

304. Kempf W, Kazakov DV, Cozzio A, et al. Primary cutaneous CD8(+) small- to medium-sized lymphoproliferative disorder in extrafacial sites: clinicopathologic features and concept on their classification. *Am J Dermatopathol.* 2013;35(2): 159-166.

305. Maubec E, Marinho E, Laroche L, Mitchell A, Grange F, Petrella T. Primary cutaneous acral CD8$^+$ T-cell lymphomas relapse more frequently in younger patients. *Br J Haematol.* 2019;185(3):598-601.

306. Kluk J, Kai A, Koch D, et al. Indolent CD8-positive lymphoid proliferation of acral sites: three further cases of a rare entity and an update on a unique patient. *J Cutan Pathol.* 2016;43(2):125-136.

307. Wobser M, Roth S, Reinartz T, Rosenwald A, Goebeler M, Geissinger E. CD68 expression is a discriminative feature of indolent cutaneous CD8-positive lymphoid proliferation and distinguishes this lymphoma subtype from other CD8-positive cutaneous lymphomas. *Br J Dermatol.* 2015;172(6):1573-1580.

308. Toberer F, Christopoulos P, Lasitschka F, Enk A, Haenssle HA, Cerroni L. Double-positive CD8/CD4 primary cutaneous acral T-cell lymphoma. *J Cutan Pathol.* 2019; 46(3):231-233.

309. Emile JF, Cohen-Aubart F, Collin M, et al. Histiocytosis. *Lancet.* 2021;398(10295): 157-170.

310. Jaffe ES, Harris NL, Stein H, Isaacson PG. Classification of lymphoid neoplasms: the microscope as a tool for disease discovery. *Blood.* 2008;112(12):4384-4399.

311. Diamond EL, Durham BH, Ulaner GA, et al. Efficacy of MEK inhibition in patients with histiocytic neoplasms. *Nature.* 2019; 567(7749):521-524.

312. Egan C, Nicolae A, Lack J, et al. Genomic profiling of primary histiocytic sarcoma reveals two molecular subgroups. *Haematologica.* 2020;105(4):951-960.

313. Shanmugam V, Griffin GK, Jacobsen ED, Fletcher CDM, Sholl LM, Hornick JL. Identification of diverse activating mutations of the RAS-MAPK pathway in histiocytic sarcoma. *Mod Pathol.* 2019;32(6): 830-843.

314. Chang KTE, Tay AZE, Kuick CH, et al. ALK-positive histiocytosis: an expanded clinicopathologic spectrum and frequent presence of KIF5B-ALK fusion. *Mod Pathol.* 2019;32(5):598-608.

315. Kemps PG, Picarsic J, Durham BH, et al. ALK-positive histiocytosis: a new clinicopathologic spectrum highlighting neurologic involvement and responses to ALK inhibition. *Blood.* 2022;139(2): 256-280.

316. Chan JK, Lamant L, Algar E, et al. ALK+ histiocytosis: a novel type of systemic histiocytic proliferative disorder of early infancy. *Blood.* 2008;112(7):2965-2968.

317. Jiang XN, Zhang Y, Xue T, et al. New clinicopathologic scenarios of EBV+ inflammatory follicular dendritic cell sarcoma: report of 9 extrahepatosplenic cases. *Am J Surg Pathol.* 2021;45(6): 765-772.

318. Gong S, Auer I, Duggal R, Pittaluga S, Raffeld M, Jaffe ES. Epstein-Barr virus-associated inflammatory pseudotumor presenting as a colonic mass. *Hum Pathol.* 2015;46(12):1956-1961.

319. Arber DA, Kamel OW, van de Rijn M, et al. Frequent presence of the Epstein-Barr virus in inflammatory pseudotumor. *Hum Pathol.* 1995;26(10):1093-1098.

Downloaded from ashpublications.org/blood/article-pdf/140/11/1229/1921035/bloodbld2022015851c.pdf by guest on 15 September 2026